

Original
Contributions

CARE OF THE BARIATRIC SURGERY PATIENT IN THE EMERGENCY DEPARTMENT

Samuel D. Luber, MD, MPH,* David R. Fischer, MD,† and Arvind Venkat, MD‡

*Department of Surgery/Division of Emergency Medicine, University of Texas-Southwestern Medical Center, Dallas, Texas, †Department of Surgery and ‡Department of Emergency Medicine, University of Cincinnati College of Medicine, Cincinnati, Ohio
Reprint Address: Arvind Venkat, MD, Department of Emergency Medicine, University of Cincinnati College of Medicine, PO Box 670769, 231 Albert Sabin Way, Cincinnati, OH 45267-0769

□ **Abstract**—Obesity has reached epidemic proportions in the United States, with an estimated 50% of adults meeting the definition of being overweight. As this condition has become more prevalent, bariatric surgery has become an increasingly accepted form of treatment of the severely obese. Patients who have had bariatric surgery are presenting more commonly to Emergency Departments as a result. This article will review the most common bariatric surgery procedures, the complications that can arise post-operatively, and the approach to the assessment and management of the bariatric surgery patient in the Emergency Department. © 2008 Elsevier Inc.

□ **Keywords**—bariatric surgery; obesity; Emergency Department

INTRODUCTION

Obesity has become one of the most prevalent conditions in the United States. More than 50% of adults meet the clinical definition of being overweight or obese, and 5% are considered severely obese (1). Obese individuals are at elevated risk for a number of conditions that can increase mortality, including Type II diabetes, hypertension, hyperlipidemia, obstructive sleep apnea, asthma, cardiovascular disease, gallbladder disease, and obstetric complications (2,3). As a result, obesity is one of the most common causes of preventable mortality in the United States (4). Unfortunately, medical treatment and

dietary and lifestyle changes have proven to be of minimal benefit to those who are morbidly obese (1,5). However, surgical treatment of obesity provides morbidly obese individuals with sustained weight loss and significant reductions in the diseases associated with excess weight (6).

There has been a dynamic growth in the number of bariatric surgical procedures for obesity. From 1990 to 2000, the national annual rate of bariatric surgery increased nearly six-fold, from 2.4 to 14.1 per 100,000 adults (7). Recently, less invasive techniques, specifically laparoscopic bariatric surgery, have become commonplace in the treatment of morbid obesity. This review will discuss the most common surgical procedures for the treatment of obesity, the complications that can arise post-operatively, and the assessment and management of the bariatric surgery patient who presents to the Emergency Department (ED).

SURGICAL STRATEGIES FOR THE TREATMENT OF OBESITY

In 2000, the National Institutes of Health published an evidence-based guideline for the surgical management of obesity. Patients are eligible for bariatric surgery if they have failed attempts at non-surgical management and have a body mass index, defined as weight in kilograms

divided by height in meters squared, > 35 with a physiologically related co-morbidity, such as type II diabetes, or > 40 years of age without a co-morbidity (1).

There are two main strategies for surgically induced weight loss—gastric restriction and intestinal malabsorption. Procedures involving gastric restriction cause early satiety by creating a small gastric pouch, which limits the volume of solid food that can be ingested in a given period of time. Satiety is also prolonged by creation of a small gastric outlet. Restrictive procedures involve gastropasty and gastric banding. It was determined early in the development of these procedures that the gastric outlet needed to be reinforced to prevent dilatation. Therefore, a prosthetic material is often used to reinforce the gastric outlet. Both the pouch and the outlet need to be small enough to restrict intake and increase satiety, but large enough to prevent obstruction. Special adjustable band systems have been developed to allow for fine adjustments of the gastric outlet diameter. Despite the fact that significant dietary compliance is required with restrictive operations, the benefits of these procedures include the technical simplicity with no staples, anastomoses, or bypasses of the intestinal tract.

Malabsorptive procedures used today include the biliopancreatic diversion with or without duodenal switch and the distal gastric bypass. Malabsorptive surgeries involve some degree of gastric volume reduction but, more importantly, rely on the bypass of various lengths of the small intestine. Functionally, this creates what has been described as a “controlled short-gut syndrome.” Benefits of these procedures include a greater sustained weight loss that is less dependent on the patient’s dietary compliance (8).

BARIATRIC SURGERY PROCEDURES

Restrictive Procedures

Vertical banded gastroplasty. Vertical banded gastroplasty is a restrictive procedure that involves creating a small (30–50 mL), vertically oriented pouch with a narrow gastric outlet (Figure 1). The pouch is created by stapling the front wall of the stomach to the back below the gastroesophageal junction. The distal end of the newly created pouch is constricted with either a 1-cm diameter polypropylene band or a 1-cm silastic ring. These procedures have not been found to be as effective as other bariatric procedures in achieving long-term reduction in excess weight; only 25–45% of patients maintain their weight loss at 10 year follow-up (9,10).

Gastric banding. Gastric banding is a purely restrictive procedure that involves placing a silastic band below the

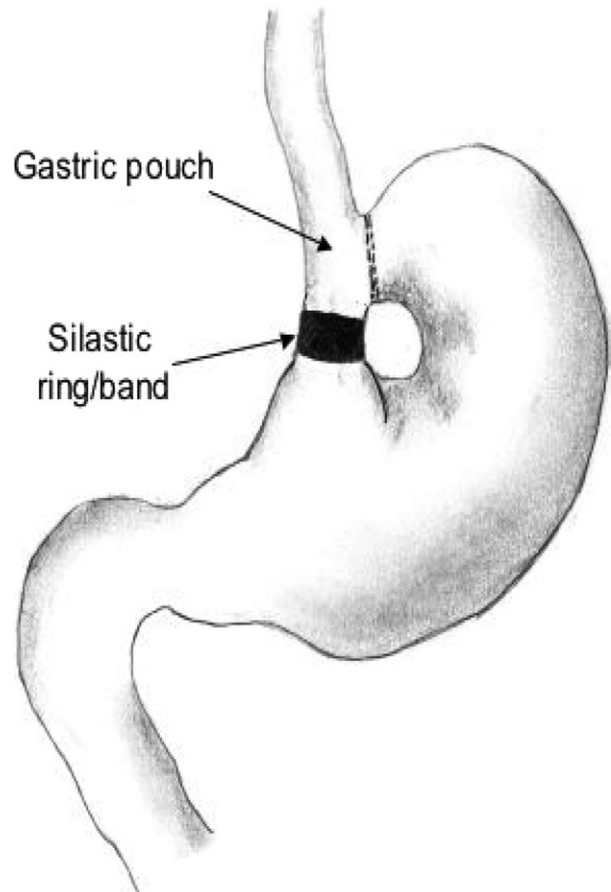


Figure 1. Vertical banded gastroplasty. A vertical pouch is created by stapling the front of the stomach to the back wall, below the esophagogastric junction. The end of the newly created gastric pouch is constricted with either a 1-cm diameter polypropylene band or a 1-cm silastic ring (vertical ring-banded gastroplasty). Reprinted with permission from *Medscape General Medicine* 6(2), 2004. <http://www.medscape.com/viewarticle/471952> © 2004 Medscape.

gastroesophageal junction to restrict oral intake. This simple procedure does not involve surgically entering the gastrointestinal tract; therefore, operative risk and complication rates are reduced (11). Recently, a newer gastric banding technique involving an adjustable band has been approved for use in the United States (Figure 2). This technique involves laparoscopically placing an adjustable band around the upper stomach. This band is connected to a port is placed subcutaneously that can be accessed to inflate or deflate the band. By altering the amount of fluid in the band, the circumference of the band changes, thus altering the diameter of the outlet. This technique is the most popular bariatric surgery performed outside of the United States (12). Although long-term results have been favorable in Europe, this surgery has not demonstrated similar success in the United States (13–15).

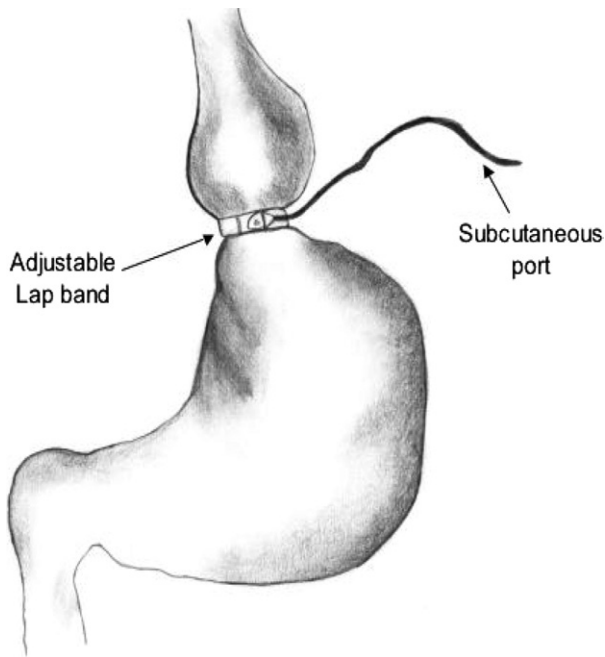


Figure 2. Adjustable laparoscopic banding. A band is laparoscopically placed around the upper stomach to create a restrictive pouch. The balloon in the band is connected to a port that is placed subcutaneously and can be accessed to inflate or deflate the balloon, consequently changing the size of the band circumference. Reprinted with permission from *Medscape General Medicine* 6(2), 2004. <http://www.medscape.com/viewarticle/471952> © 2004 Medscape.

Malabsorptive Procedures

Gastric bypass. Roux-en-Y gastric bypass involves both restrictive and malabsorptive components and has become the most common bariatric surgery performed in the United States (Figure 3). This procedure is estimated to be performed in the United States approximately 70,000 times per year, 70% of the total gastric bypass surgeries performed domestically (16). The diversionary component is the Roux limb, which bypasses the distal stomach, duodenum, and upper jejunum, and contributes to weight loss by causing malabsorption of calories and inducing a dumping syndrome. There are multiple variations in this procedure, but generally, a 15–50-mL gastric pouch is created with a 75–150-cm Roux-limb connected as an enteroenterostomy to the jejunum, 30–50 cm distal to the ligament of Treitz.

Biliopancreatic diversion. Biliopancreatic diversion is a two-component procedure: a limited gastrectomy and the creation of a long-limb Roux-en-Y anastomosis with a short, 50-cm alimentary channel (Figure 4A). The short channel is created by transecting the small intestine approximately 250 cm from the ileocecal valve and attaching the distal end to the gastric pouch. The proximal end

is then joined near the ileocecal valve. This procedure leaves no defunctionalized small intestine. The biliopancreatic diversion can lead to significant weight loss through a decrease in oral intake and induction of significant malabsorption of fat by diverting bile and pancreatic secretions. Successful weight loss has been reported above 65–75% of excess body weight at 18 years post-surgery (17,18).

Biliopancreatic diversion with duodenal switch is a promising alternative to a standard biliopancreatic diversion (Figure 4B). This procedure involves a sleeve gastrectomy involving 70–80% of the greater curvature of the stomach, maintenance of the pylorus and a small part of the duodenum, and the construction of a Roux-en-Y duodenoenterostomy. The benefit of this adaptation is that the maintenance of the pylorus and duodenal system reduces the post-operative malabsorption complications, such as stomal ulceration.

Laparoscopic approaches. Laparoscopic bariatric surgery procedures have been emerging since the mid-1990s. Advantages over open procedures include reduced peri-operative morbidity, mostly wound related, and shorter recovery times (19,20). Laparoscopic techniques have additional challenges in morbidly obese patients, such as the greater distance through the abdominal wall, and hand-assisted laparoscopic techniques

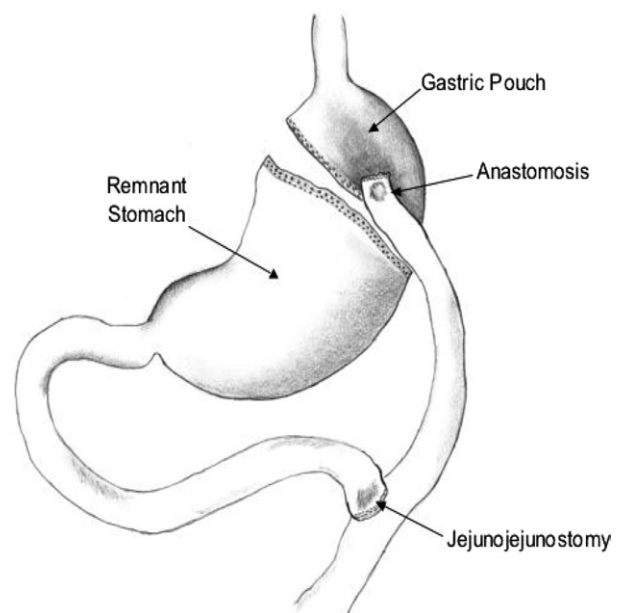


Figure 3. Roux-en-Y gastric bypass surgery. A small pouch is created by either stapling or transecting the stomach. The pouch is then connected to and empties into the Roux limb of the jejunum, which is approximately 50–100 cm in length. Reprinted with permission from *Medscape General Medicine* 6(2), 2004. <http://www.medscape.com/viewarticle/471952> © 2004 Medscape.

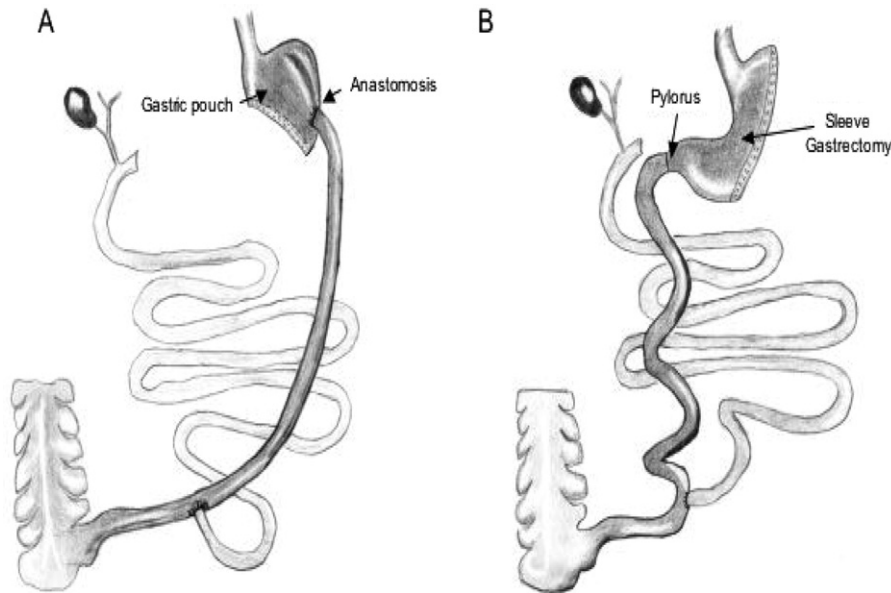


Figure 4. (A) Biliopancreatic diversion. A limited gastrectomy is created, and the transected ileum is anastomosed to the gastric pouch. (B) Biliopancreatic diversion with duodenal switch. A sleeve gastrectomy is created to maintain the pylorus and avoid anastomotic complications. Similar to classic biliopancreatic diversion, the transected, distal small bowel is connected to the stomach via a small part of the first portion of the duodenum. Reprinted with permission from *Medscape General Medicine* 6(2), 2004. <http://www.medscape.com/viewarticle/471952> © 2004 Medscape.

have been developed (21). The laparoscopic Roux-en-Y gastric bypass procedure has been described as one of the most technically challenging laparoscopic procedures to date (22).

COMPLICATIONS OF BARIATRIC SURGERY

Outcomes after bariatric surgery have dramatically improved over the last two decades. Hospital stays are more commonly 3–4 days as opposed to 9–10 days in the past (23). During the 1980s, one review found that 9% of patients had peri- and post-operative respiratory complications, 4% had anastomotic leaks, and 6% required repeat surgical intervention (24). Today, perioperative mortality of bariatric surgery is less than 1% (25,26).

Surgical Complications

There are a number of surgical complications of bariatric procedures that can present to the ED (Table 1). The most common cause of death after bariatric surgery is peritonitis from an anastomotic breakdown. This is typically an early complication, usually diagnosed within 10 days after surgery. The incidence of post-operative leak after Roux-en-Y gastric bypass ranges from 1–6% (27). Specifically, this has been noted to occur in 1.2% of open cases and 3% of laparoscopic cases (28). The classic

peritoneal signs are not always present post-operatively, and the emergency physician must be aware of subtle signs and symptoms that may point to this diagnosis requiring early surgical consultation. These include fever, increasing abdominal pain, back pain, pelvic pressure, hiccups, unexplained tachycardia, and restlessness. A pulse rate that remains above 120 beats/min has been associated with gastric dilatation and leak with peritonitis (29). Given the seriousness of this complication and the vague nature of the presenting symptoms, suspicion of this diagnosis should lead to early surgical consultation. Radiologic contrast studies (upper gastrointestinal series) are essential to aid in the diagnosis of post-operative leak. These are routinely performed as part of

Table 1. Surgical Complications of Bariatric Procedures

Early complications (within 30 days of surgery)
Anastomotic breakdown—Roux-en-Y gastric bypass and biliopancreatic diversion
Acute gastric distention—Roux-en-Y gastric bypass
Late complications (more than 30 days past surgery)
Incisional hernias—open bariatric surgical procedures
Internal hernias—Roux-en-Y gastric bypass
Stomal stenosis—Roux-en-Y gastric bypass
Band erosion/Migration—vertical banded gastroplasty and adjustable gastric banding
Staple line disruption—Roux-en-Y gastric bypass and biliopancreatic diversion
Early or late complication
Small bowel obstruction—Roux-en-Y gastric bypass

the post-operative management of bariatric surgery patients to define the post-operative anatomy and to assess for leak, ileus, or obstruction. However, radiologic contrast studies can be non-diagnostic and are not extremely sensitive for anastomotic leak, and often, re-exploration in the operating room is performed early in the evaluation if this diagnosis is suspected. Initial reports of complications with laparoscopic procedures demonstrated higher anastomotic leaks, but as surgeons are becoming more experienced with the procedures, complication rates are decreasing (30).

Acute gastric distention can occur after open or laparoscopic Roux-en-Y gastric bypass. This complication seems to be due to edema or obstruction at the enteroenterostomy site. Most cases develop within the first several days post-operative, and patients will present with nausea, vomiting (dry heaves), left upper quadrant bloating, and hiccups (31). Severe distention can create problems with staple lines and anastomoses. Plain radiographs may demonstrate significant gastric distension with air-fluid levels. Percutaneous decompression has been successful in some, whereas others require re-operation with gastrostomy tube placement (28). There is some controversy as to whether nasogastric tube decompression is warranted should distention of the proximal pouch or small bowel obstruction be found. A distended remnant stomach will not be decompressed by a nasogastric tube. It is prudent to discuss this intervention with a consulting surgeon before placement in the ED due to the potential risk for puncturing suture lines.

Incisional hernias occur in 15–20% of patients after open gastric bypass, and lack of this complication is one of the major advantages of the laparoscopic approach (28). However, given the body habitus of patients undergoing gastric bypass surgery, hernias can at times be hard to palpate, and imaging by computed tomography may be required to make the definitive diagnosis. Unless the patient is symptomatic from the hernia due to incarceration or strangulation, it has been suggested to wait for maximal weight loss before repair. A hernia repair and panniculectomy (excision of excessive skin and subcutaneous tissue post weight loss) can then be completed as one procedure (28). Incarcerated hernias can occur at port sites as well and are difficult to appreciate on examination. In one of the author's experience, they are a cause of early morbidity and need for re-operation.

Internal hernias can occur after Roux-en-Y gastric bypass; they are said to occur in up to 6% of patients (32). Internal hernias can develop in the transverse mesocolon where the limb passes through, around the mesentery of the roux limb, or in the mesenteric defect at the enteroenterostomy (28). They have been reported to occur more frequently with the laparoscopic approach (33). These hernias are difficult to identify both clinically and

radiographically. As with any patient, pain out of proportion to examination should alert the clinician to the possibility of bowel ischemia. Radiographic studies are often non-specific, and surgical intervention for visualization may be necessary (28). A dilated gastric remnant and oral contrast refluxing into the remnant may suggest internal hernia or distal obstruction.

Stomal stenosis occurs in up to 12% of both gastric bypass and vertical banded gastroplasty procedures and typically occurs 1 or more months after surgery, with a mean of 49 days after Roux-en-Y gastric bypass (34–36). The gastric outlet of both procedures is typically designed to be 1 cm in diameter. Stenosis of the outlet can lead to symptoms of post-prandial epigastric pain and vomiting. Treatment involves endoscopy with balloon dilatation. Some patients require multiple dilatations.

Band erosion into the stomach after gastric banding has been reported in 0.3–1.9% of patients. Patients with this complication may present with progressive left upper quadrant pain or pain in the left lower chest that can mimic complaints of angina (22). Outlet obstruction can also lead to severe gastroesophageal reflux and esophagitis. Conversion to a gastric bypass may be required to resolve this complication.

Small bowel obstruction may occur in the early or late post-operative period. It has been described in up to 5% of patients after Roux-en-Y gastric bypass. Etiologies include adhesions, internal hernia, and intussusception (27). As in other post-operative patients, flat and upright plain radiography of the abdomen will often reveal this diagnosis. Great care needs to be taken in nasogastric decompression of these patients due to the potential for suture line and anastomotic puncture. Although the incidence of small bowel obstruction seems to be lower in the laparoscopic approach, there is an increased risk of internal hernia with laparoscopic technique. Most hernias are diagnosed more than 1 month after surgery (37). Diagnosis can be made with the use of plain radiography.

Staple line disruption is a complication of Roux-en-Y gastric bypass and vertical banded gastroplasty and is more of a weight-loss complication than a surgical complication. This may occur in the early post-operative period, but more commonly occurs 4 or more months after surgery (27). This complication allows the excluded stomach to communicate with the gastric pouch, which can lead to inadequate weight loss. It may manifest as a fistula between the pouch and gastric remnant on a contrast radiologic study. Patients may also present to the ED with complaints of gastrointestinal bleeding, which may be attributed to bleeding from the suture line of the Roux-en-Y gastric bypass limb. This complication may require aggressive management, including large-bore intravenous access and fluid and blood resuscitation, given the decreased oral intake of gastric bypass patients and

the resultant potential acceleration of the deterioration in volume status (31).

Pulmonary Complications

Deep vein thrombosis with resultant pulmonary embolism is the second most common cause of death after bariatric surgery, with an incidence of 2% and a mortality of 20–30%, and does not seem related to the type of surgery (28,31). This can occur in the immediate post-operative period and as long as a month after the procedure (28). The ED algorithm for diagnosis of thromboembolic disease is unchanged in the post-operative patient. However, post-operative leaks or peritonitis may masquerade as a pulmonary complication with tachycardia and tachypnea. In one study, those with tachycardia and respiratory distress had a 20% incidence of anastomotic leak (38).

Nutritional Complications

Malnutrition is uncommon in patients with restrictive procedures, such as vertical banded gastroplasty, but does occur with malabsorptive procedures. Iron and calcium are absorbed in the duodenum, which leads to these deficiencies in the bypass patient. Iron-deficiency anemia has been described in 20–49% of patients (30). Treatment is with ferrous sulfate. Studies have also demonstrated that between 26% and 70% of patients may develop vitamin B12 deficiencies (30). This is thought to occur due to the failure of food-bound vitamin B12 to be cleaved in the upper gastric pouch (31). Patients undergoing malabsorptive procedures are typically placed on multivitamins as well as calcium supplementation post-operatively. Individuals who have undergone gastroplasty are less likely to develop these complications as opposed to the gastric bypass patient.

Malabsorptive procedures such as the biliopancreatic diversion can cause protein-calorie malabsorption in 7.7–11.9% of patients (4). In one series, at 2-year follow-up, 33% of patients undergoing biliopancreatic diversion had developed anemia (28). Hypoalbuminemia also has been described (39). Biliopancreatic diversion with duodenal switch demonstrates a lower incidence of protein-calorie malnutrition, with 2–3% of patients developing problems (28).

Hepatobiliary Complications

Gallstone formation after bariatric surgery is common. It is felt to be related to the rapid weight loss and resultant

bile stasis with biliary sludge formation. The incidence of sludge in the gallbladder is up to 50% at post-operatively, with an incidence of gallstones at 32% (40). Prophylactic treatment with ursodiol for 6 months after surgery has been shown to reduce the incidence of gallstones to 2% (40,41). After a Roux-en-Y gastric bypass, access to the biliary tree may be impossible via endoscopic retrograde cholangiopancreatography. Thus, the diagnosis of choledocholithiasis becomes problematic. Prophylactic cholecystectomy is performed by some surgeons, whereas others believe it increases operative complications (4). If this diagnosis is suspected in the ED, abdominal ultrasonography can aid in making the diagnosis along with adjunctive laboratory testing such as liver function tests, complete blood cell count, and pancreatic enzyme evaluation.

Gastrointestinal Complications

Stomal ulceration has been demonstrated in up to 15% of gastric bypass patients, although the etiology is unclear. Patients typically present within the first 90 days after surgery and complain of severe dyspepsia, burning retrosternal pain, and vomiting. Ulceration is diagnosed by direct visualization with endoscopy. Treatment involves proton pump inhibitors, carafate or sucralfate, and antibiotics if the patient is found to be *H. pylori* positive (28).

Dumping syndrome, in which the patient complains of pain, satiety, nausea and vasomotor symptoms (diaphoresis, weakness, dizziness, flushing), is commonly seen in gastric bypass patients. It has been described in up to 75% of patients. Some attribute the success of the procedure to this effect, because it deters the ingestion of calorie-dense liquids, but this has not been well established (4). Small frequent meals, dry meals, avoidance of simple sugars, and various other dietary modifications have been advocated to help control symptoms. In severe dumping syndrome, octreotide has been recommended to slow gastric emptying (42).

Neurological Complications

A 1987 retrospective review by Abarbanel et al. reported that 23 of 500 (4.6%) patients undergoing a bariatric surgical procedure experienced neurologic complications. The symptoms occurred anywhere from 3 to 20 months post-operatively. All of the affected patients experienced protracted vomiting. Patients also presented with neuropathies, myopathies, encephalopathy, and burning feet (43). More recent studies found that 48 of 556 (8.6%) patients who had undergone bariatric surgery had complications of the peripheral nervous system. These complications included

mononeuropathies (carpal tunnel syndrome being most common), peripheral neuropathies, plexopathies, and myopathy (44). A deficiency of vitamin B1 (thiamine) is felt to be a major contributor to the neurologic complications. A recent review notes that at least 30 cases worldwide of Wernicke encephalopathy after bariatric surgery have been published and that this condition is mostly seen within 8 to 15 weeks after surgery (45).

CONCLUSION

More and more patients are turning to surgical management for weight loss. Despite decreasing complication rates, the sheer number of procedures being performed guarantees that more post-operative patients will be seen in EDs across the country. It is imperative that emergency physicians be vigilant in the evaluation and management of these patients. A thorough search for complications, even in patients with benign physical examinations, is important. Early surgical consultation will also aid in the emergency evaluation and treatment of bariatric surgery patients.

REFERENCES

- National Institutes of Health. The practical guide. identification, evaluation, and treatment of overweight and obesity in adults (NIH Publication no. 00-4084). Bethesda, MD: National Institutes of Health, National Heart, Lung, and Blood Institute, and North American Association for the Study of Obesity; 2000.
- Overweight, obesity, and health risk. National Task Force on the Prevention and Treatment of Obesity. *Arch Intern Med* 2000;160:898–904.
- Must A, Spadano J, Coakley EH, Field AE, Colditz G, Dietz WH. The disease burden associated with overweight and obesity. *JAMA* 1999;282:1523–9.
- Stocker DJ. Management of the bariatric surgery patient. *Endocrinol Metab Clin North Am* 2003;32:437–57.
- Clinical guidelines on the identification, evaluation, and treatment of overweight and obesity in adults: evidence report (NIH Publication no. 98-4083). Available at: http://www.nhlbi.nih.gov/guidelines/obesity/ob_gdlns.htm. Accessed May 22, 2005.
- Buchwald H, Avidor Y, Braunwald E, et al. Bariatric surgery: a systematic review and meta-analysis. *JAMA* 2004;292:1724–37.
- Trus TL, Pope GD, Finlayson SR. National trends in utilization and outcomes of bariatric surgery. *Surg Endosc* 2005;19:616–20.
- Fisher BL, Schauer P. Medical and surgical options in the treatment of severe obesity. *Am J Surg* 2002;184:9S–16S.
- Sugerman HJ, Starkey JV, Birkenhauer R. A randomized prospective trial of gastric bypass versus vertical banded gastroplasty for morbid obesity and their effects on sweets versus non-sweets eaters. *Ann Surg* 1987;205:613–24.
- Balsiger BM, Poggio JL, Mai J, Kelly KA, Sarr MG. Ten and more years after vertical banded gastroplasty as primary operation for morbid obesity. *J Gastrointest Surg* 2000;4:598–605.
- Bo O, Modalsli O. Gastric banding, a surgical method of treating morbid obesity: preliminary report. *Int J Obes* 1983;7:493–9.
- Belachew M, Legrand M, Vincent V, Lismonde M, Le Docte N, Deschamps V. Laparoscopic adjustable gastric banding. *World J Surg* 1998;22:955–63.
- Belachew M, Belva PH, Desai C. Long-term results of laparoscopic adjustable gastric banding for the treatment of morbid obesity. *Obes Surg* 2002;12:564–8.
- Weiner R, Blanco-Engert R, Weiner S, Matkowitz R, Schaefer L, Pomhoff I. Outcome after laparoscopic adjustable gastric banding – 8 years experience. *Obes Surg* 2003;13:427–34.
- DeMaria EJ, Sugerman HJ, Meador JG, et al. High failure rate after laparoscopic adjustable silicone gastric banding for treatment of morbid obesity. *Ann Surg* 2001;233:809–18.
- Buchwald H, Williams SE. Bariatric surgery worldwide 2003. *Obes Surg* 2004;14:1157–64.
- Scopinaro N. Outcome evaluation after bariatric surgery. *Obes Surg* 2002;12:253.
- Scopinaro N, Gianetta E, Adami GF, et al. Biliopancreatic diversion for obesity at eighteen years. *Surgery* 1996;119:261–8.
- DeMaria EJ, Sugerman HJ, Kellum JM, Meador JG, Wolfe LG. Results of 281 consecutive total laparoscopic Roux-en-Y gastric bypasses to treat morbid obesity. *Ann Surg* 2002;235:640–5; discussion 645–7.
- Nguyen NT, Goldman C, Rosenquist CJ, et al. Laparoscopic versus open gastric bypass: a randomized study of outcomes, quality of life, and costs. *Ann Surg* 2001;234:279–89; discussion 289–91.
- Sundbom M, Gustavsson S. Hand-assisted laparoscopic bariatric surgery. *Semin Laparosc Surg* 2001;8:145–52.
- Schauer PR, Ikramuddin S. Laparoscopic surgery for morbid obesity. *Surg Clin North Am* 2001;81:1145–79.
- Livingston EH. Procedure incidence and in-hospital complication rates of bariatric surgery in the United States. *Am J Surg* 2004;188:105–10.
- Benotti PN, Hollingshead J, Mascioli EA, Bothe A Jr, Bistran BR, Blackburn GL. Gastric restrictive operations for morbid obesity. *Am J Surg* 1989;157:150–5.
- Klein S, Wadden T, Sugerman HJ. AGA technical review on obesity. *Gastroenterology* 2002;123:882–932.
- Schauer PR, Ikramuddin S, Gourash W, Ramanathan R, Luketich J. Outcomes after laparoscopic Roux-en-Y gastric bypass for morbid obesity. *Ann Surg* 2000;232:515–29.
- Carucci LR, Turner MA. Radiologic evaluation following Roux-en-Y gastric bypass surgery for morbid obesity. *Eur J Radiol* 2005;53:353–65.
- Byrne TK. Complications of surgery for obesity. *Surg Clin North Am* 2001;81:1181–93, vii–viii.
- Mason EE, Hesson WW. Informed consent for obesity surgery. *Obes Surg* 1998;8:419–28.
- Podnos YD, Jimenez JC, Wilson SE, Stevens CM, Nguyen NT. Complications after laparoscopic gastric bypass: a review of 3464 cases. *Arch Surg* 2003;138:957–61.
- Gorecki P, Wise L, Broolin RE, Champion JK. Complications of combined gastric restrictive and malabsorptive procedures: part I. *Curr Surg* 2003;60:138–44.
- Comeau E, Gagner M, Inabnet WB, Herron DM, Quinn TM, Pomp A. Symptomatic internal hernias after laparoscopic bariatric surgery. *Surg Endosc* 2005;19:34–9.
- Serra C, Baltasar A, Bou R, Miro J, Cipagauta LA. Internal hernias and gastric perforation after a laparoscopic gastric bypass. *Obes Surg* 1999;9:546–9.
- Blachar A, Federle MP. Gastrointestinal complications of laparoscopic Roux-en-Y gastric bypass surgery in patients who are morbidly obese: findings on radiography and CT. *AJR Am J Roentgenol* 2002;179:1437–42.
- Blachar A, Federle MP, Pealer KM, Ikramuddin S, Schauer PR. Gastrointestinal complications of laparoscopic Roux-en-Y gastric bypass surgery: clinical and imaging findings. *Radiology* 2002;223:625–32.
- Sanyal AJ, Sugerman HJ, Kellum JM, Engle KM, Wolfe L. Stomal complications of gastric bypass: incidence and outcome of therapy. *Am J Gastroenterol* 1992;87:1165–9.
- Higa KD, Boone KB, Ho T. Complications of the laparoscopic Roux-en-Y gastric bypass: 1,040 patients—what have we learned? *Obes Surg* 2000;10:509–13.
- Hamilton EC, Sims TL, Hamilton TT, Mullican MA, Jones DB, Provost DA. Clinical predictors of leak after laparoscopic Roux-

- en-Y gastric bypass for morbid obesity. *Surg Endosc* 2003;17:679–84.
39. Picard M, Frederic Simon H, Stefane L, Simon M, Simon B. Complications of combined gastric restrictive and malabsorptive procedures: part 2. *Curr Surg* 2003;60:274–9; discussion 279–81.
 40. Sugerman HJ, Brewer WH, Shiffman ML, et al. A multicenter, placebo-controlled, randomized, double-blind, prospective trial of prophylactic ursodiol for the prevention of gallstone formation following gastric-bypass-induced rapid weight loss. *Am J Surg* 1995;169:91–6; discussion 96–7.
 41. Miller K, Hell E, Lang B, Lengauer E. Gallstone formation prophylaxis after gastric restrictive procedures for weight loss: a randomized double-blind placebo-controlled trial. *Ann Surg* 2003;238:697–702.
 42. Carvajal SH, Mulvihill SJ. Postgastrectomy syndromes: dumping and diarrhea. *Gastroenterol Clin North Am* 1994;23:261–79.
 43. Abarbanel JM, Berginer VM, Osimani A, Solomon H, Charuzi I. Neurologic complications after gastric restriction surgery for morbid obesity. *Neurology* 1987;37:196–200.
 44. Thaisetthawatkul P, Collazo-Clavell ML, Sarr MG, Norell JE, Dyck PJ. A controlled study of peripheral neuropathy after bariatric surgery. *Neurology* 2004;63:1462–70.
 45. Berger JR. The neurological complications of bariatric surgery. *Arch Neurol* 2004;61:1185–9.