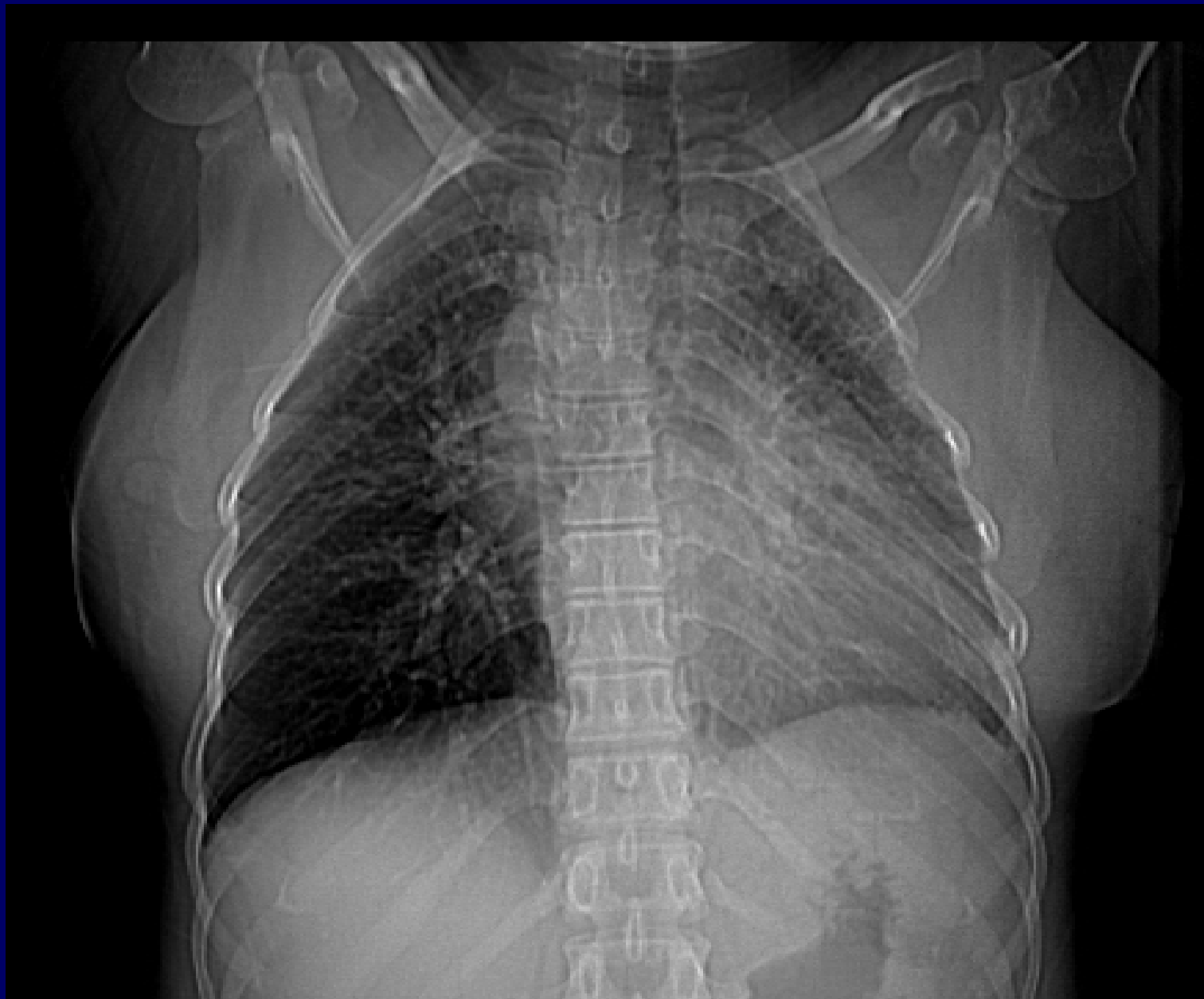

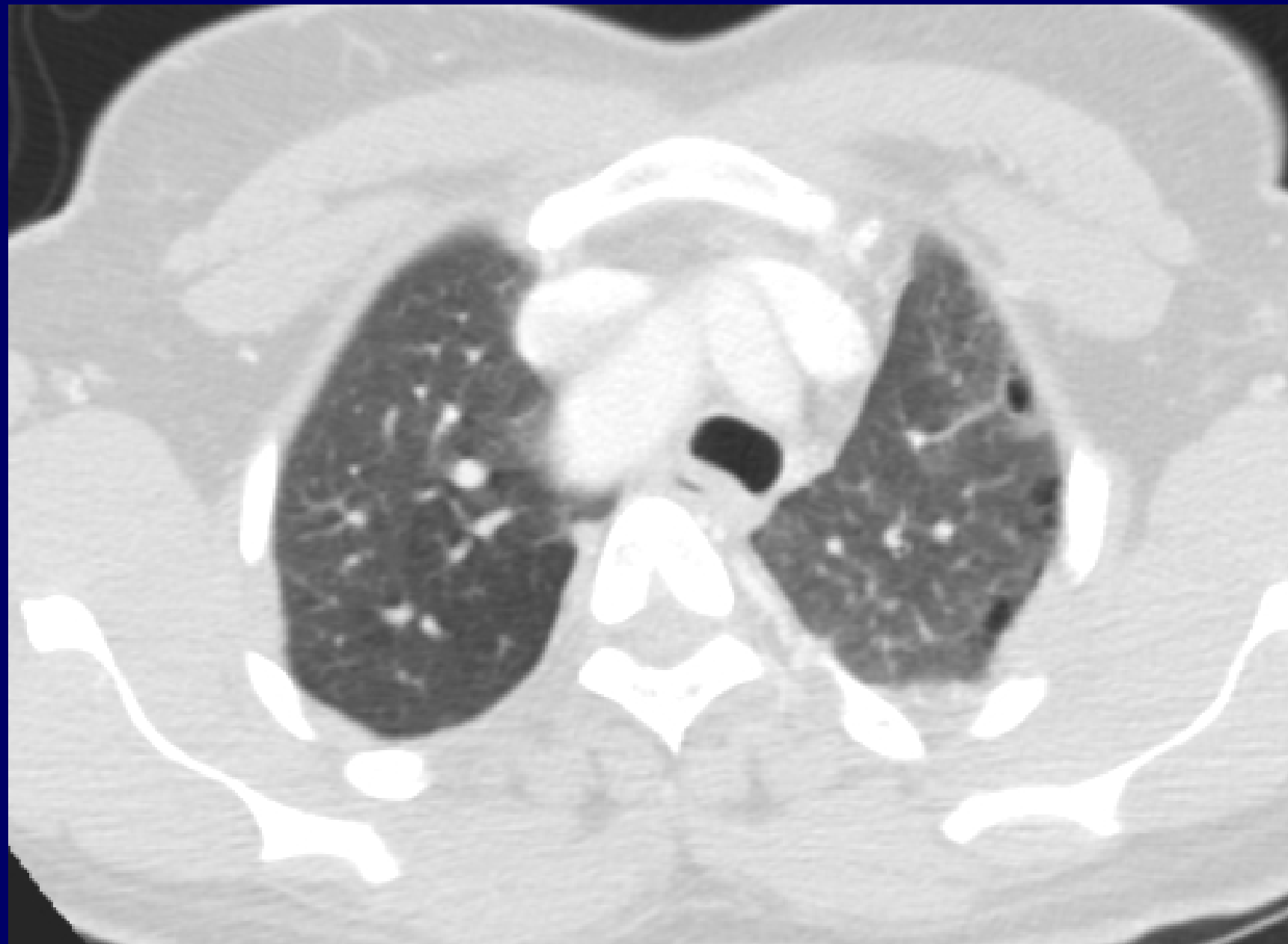Pulmonary Rounds

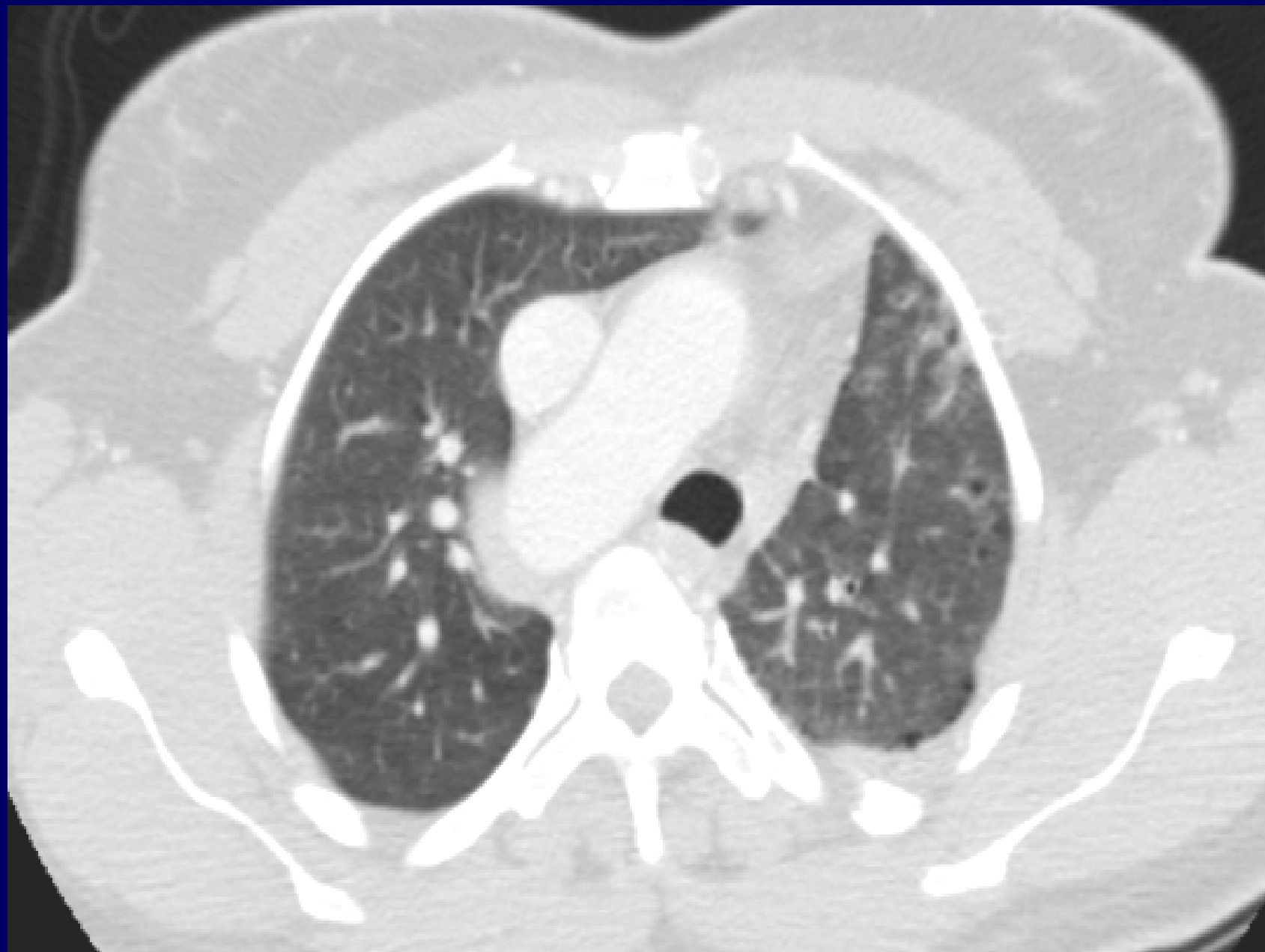Ross K Morgan MD

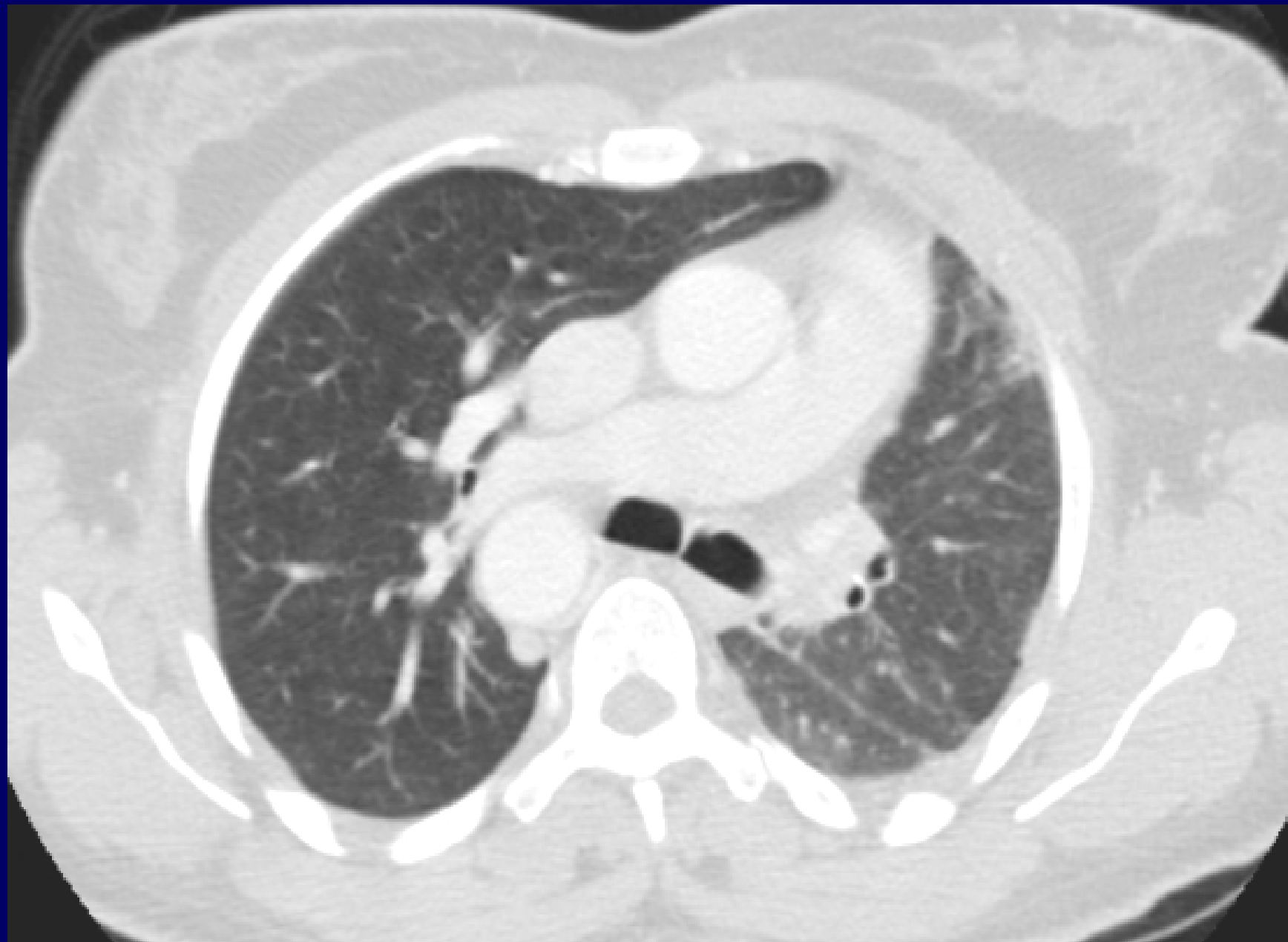
June 1st 2005

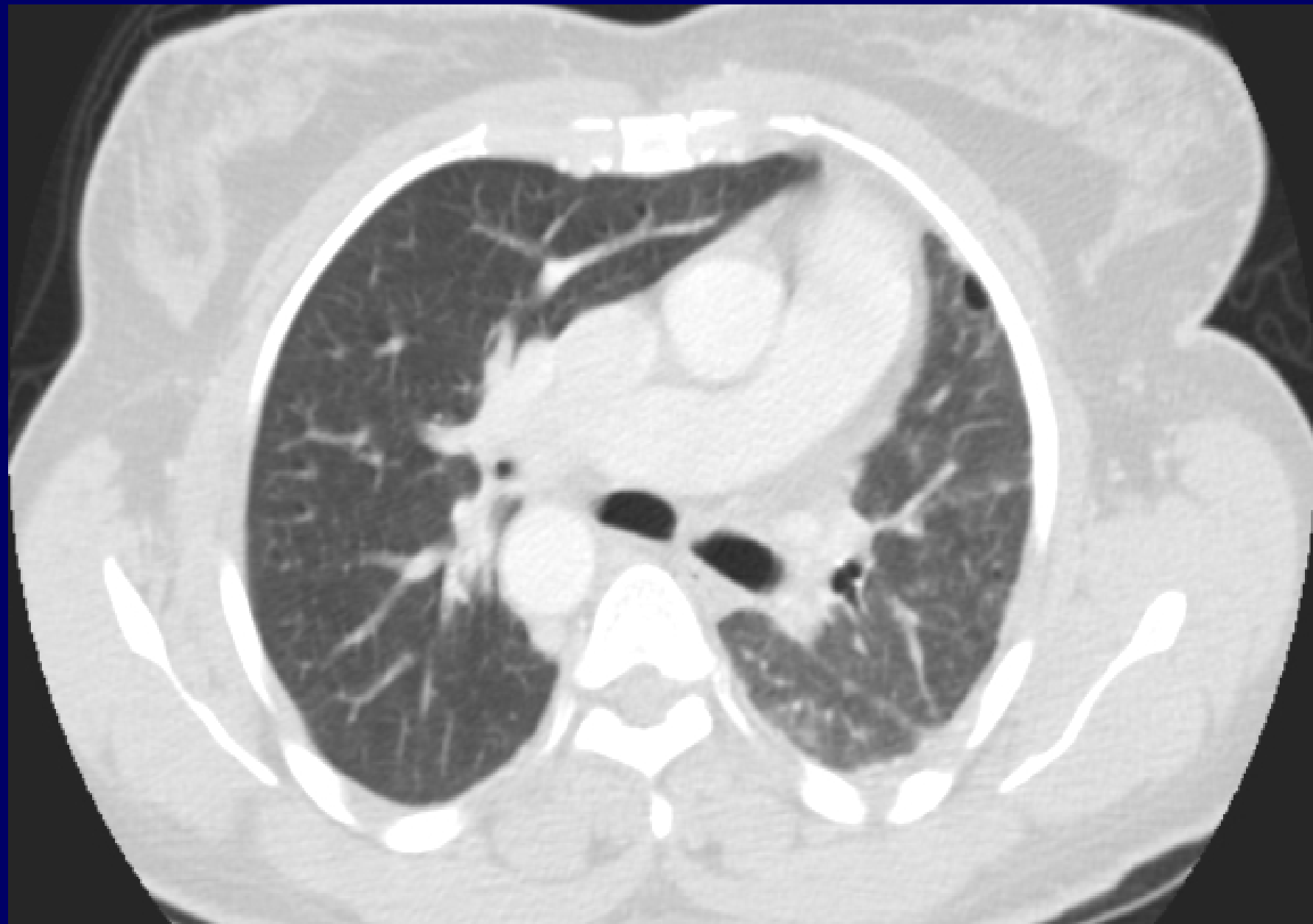- A 43 year old woman has a CXR performed for cough

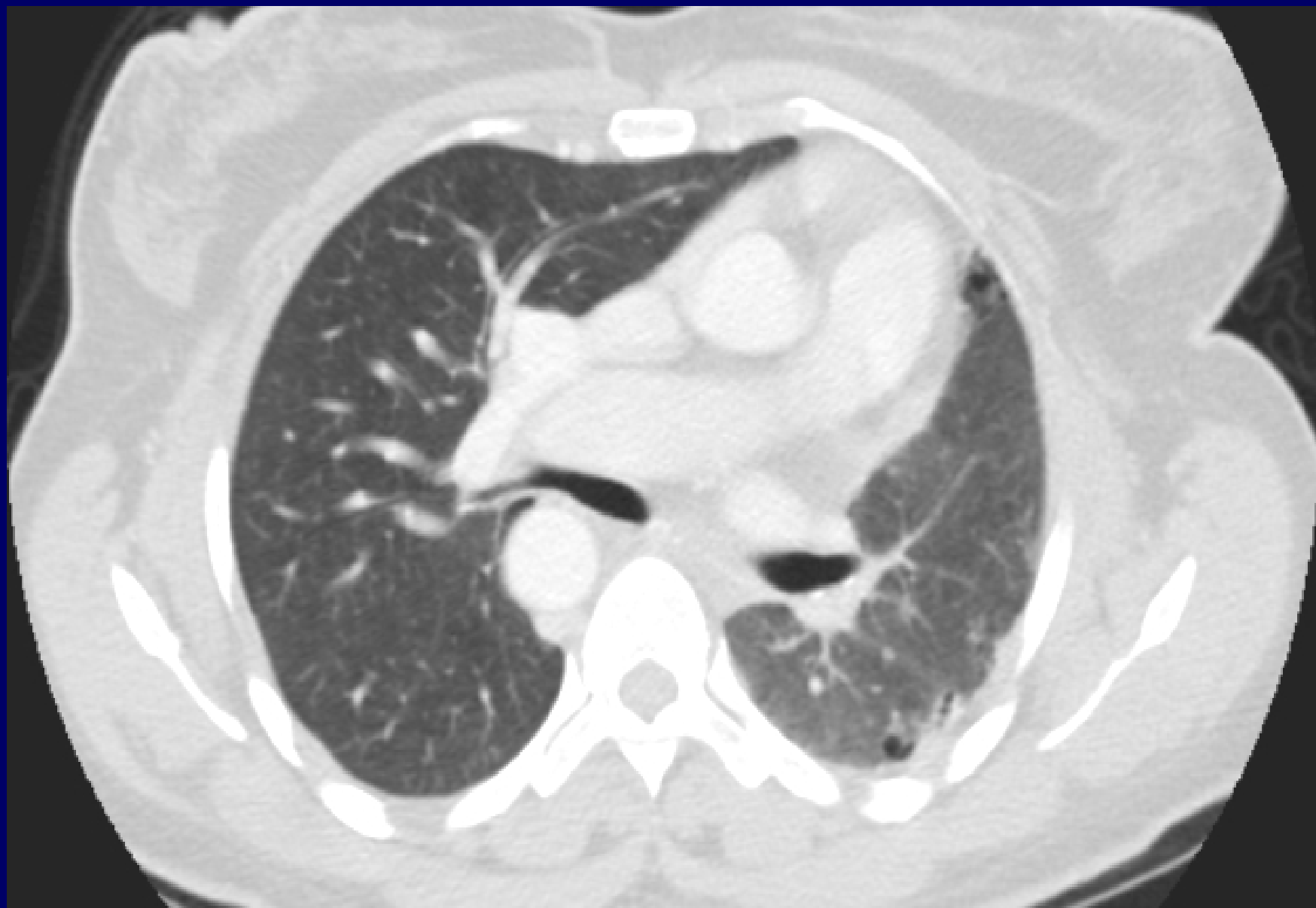


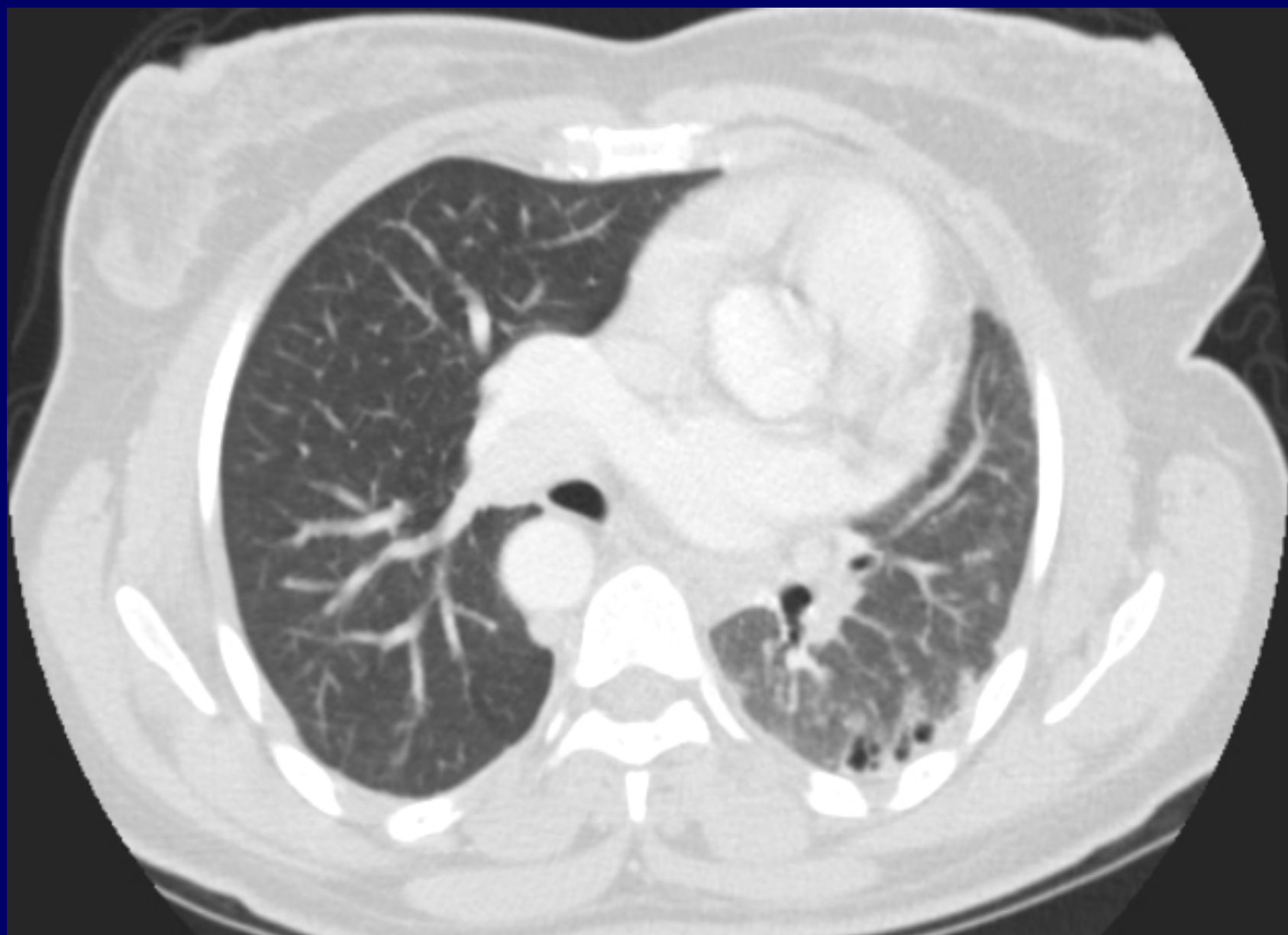

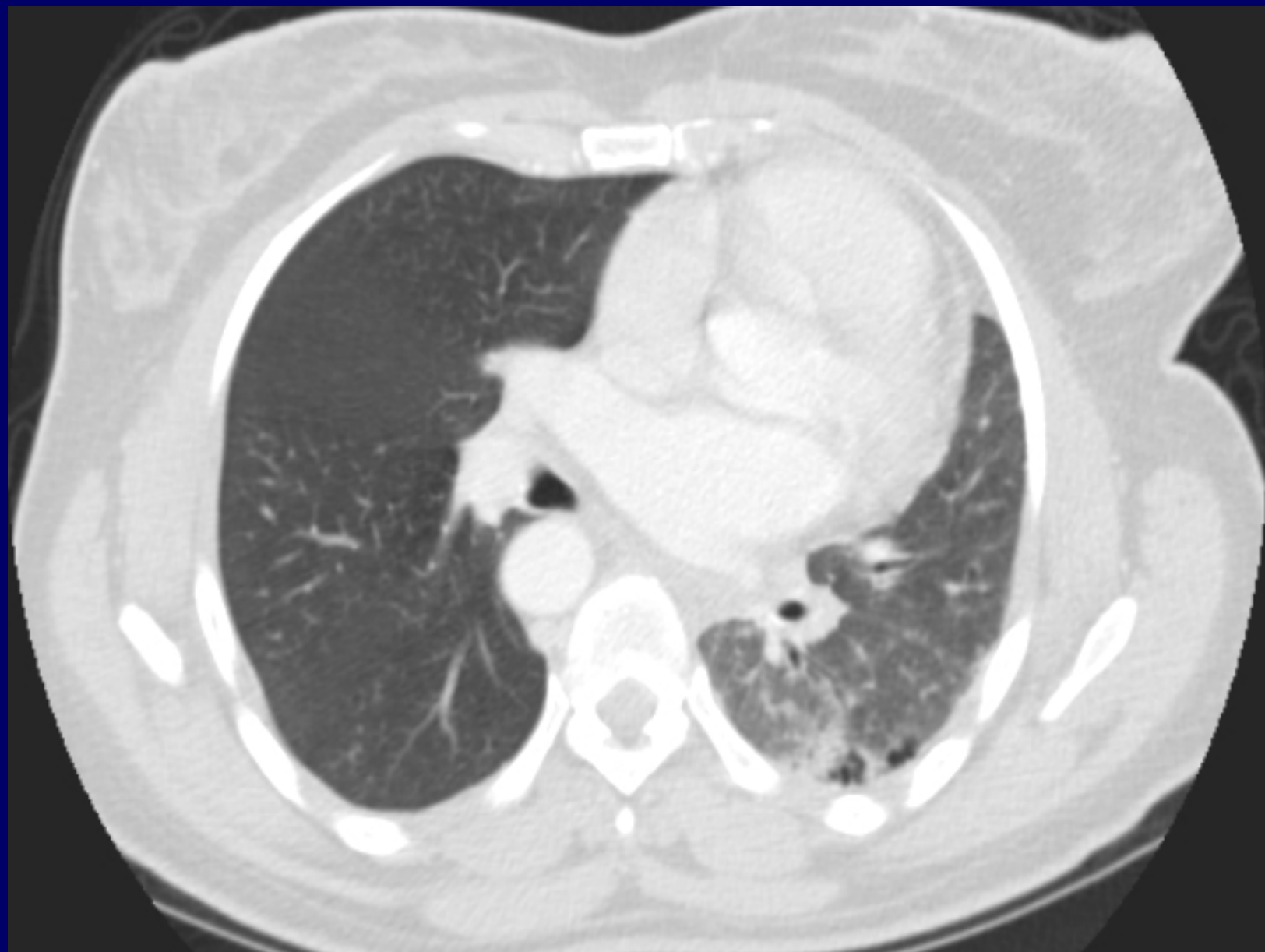


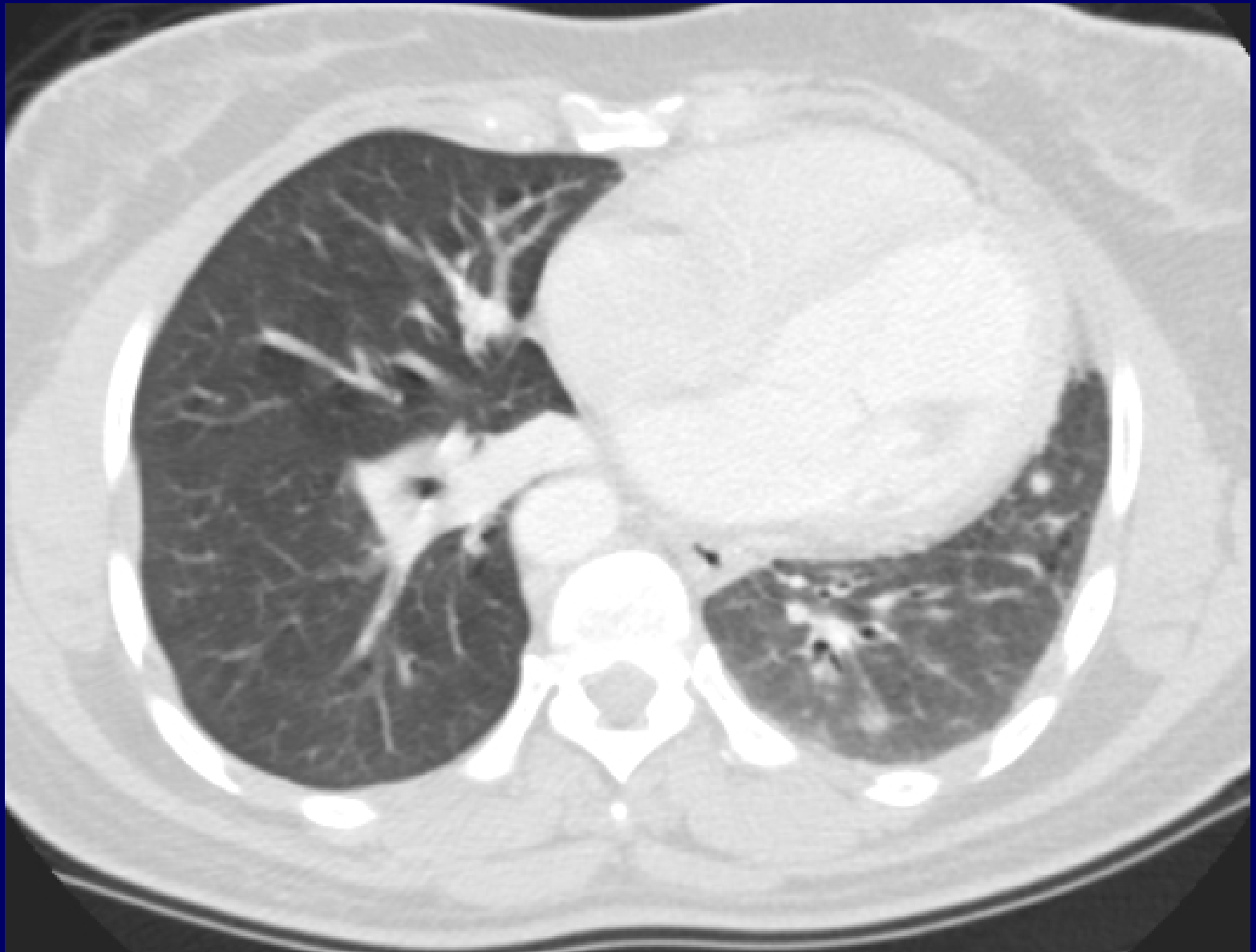



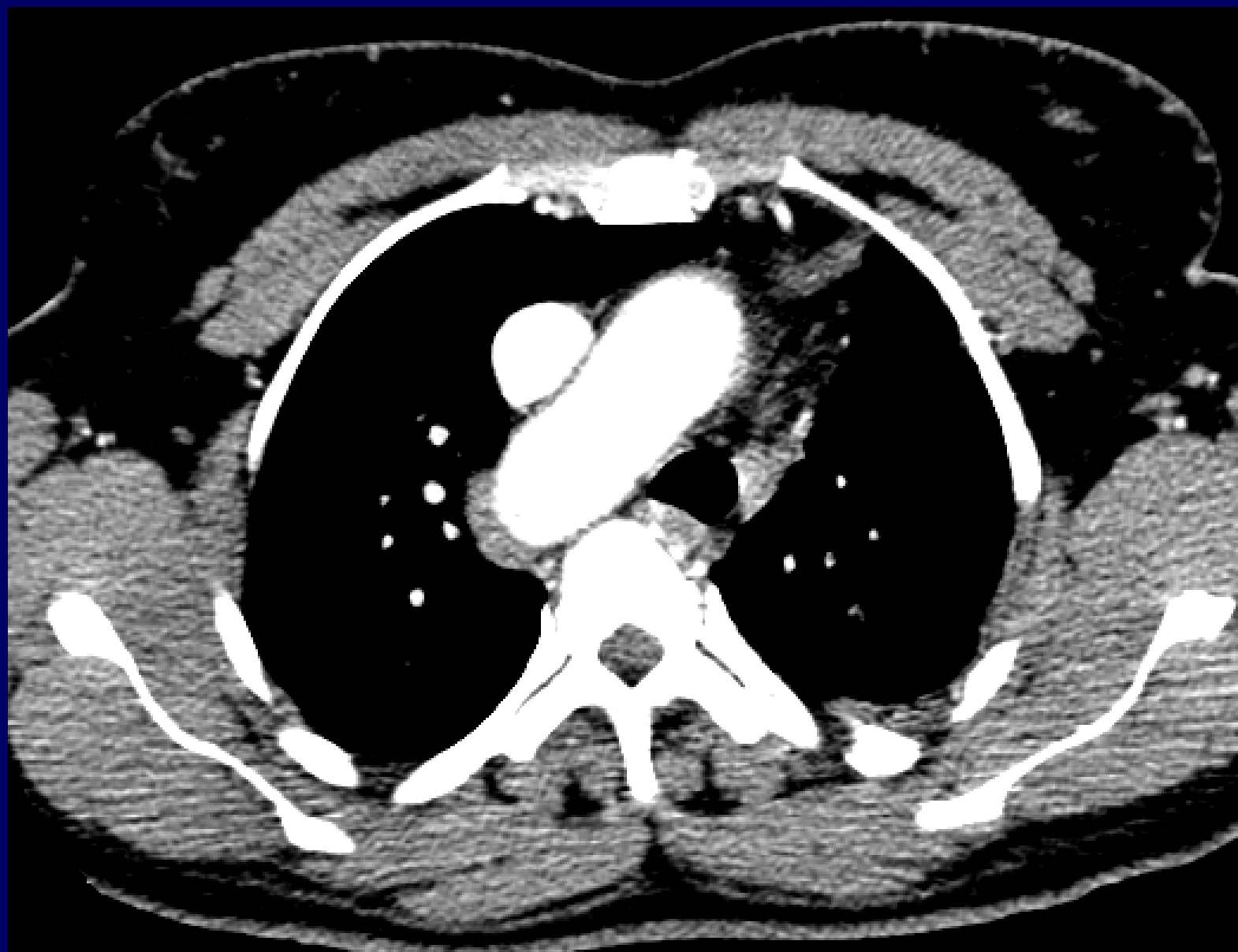


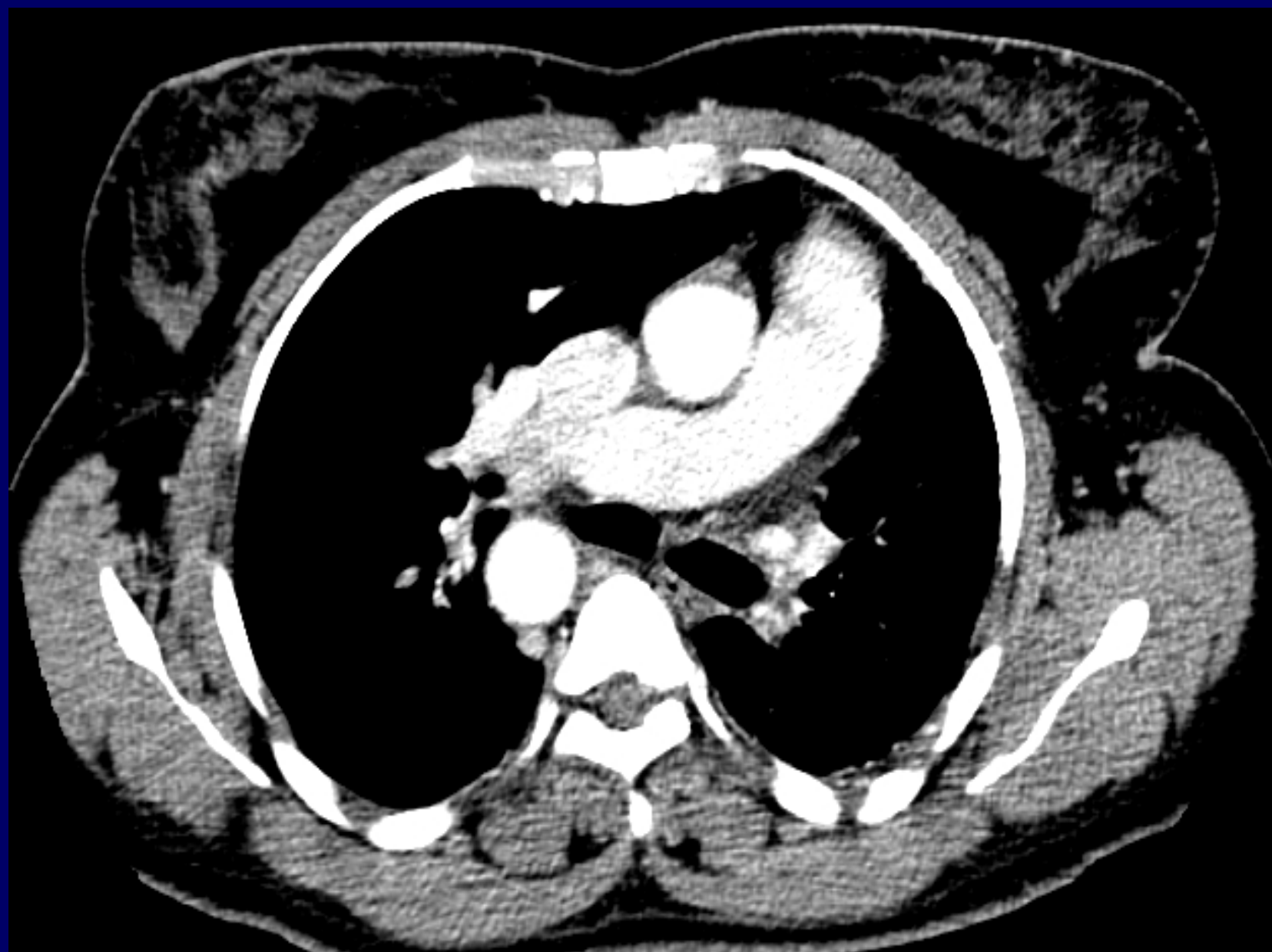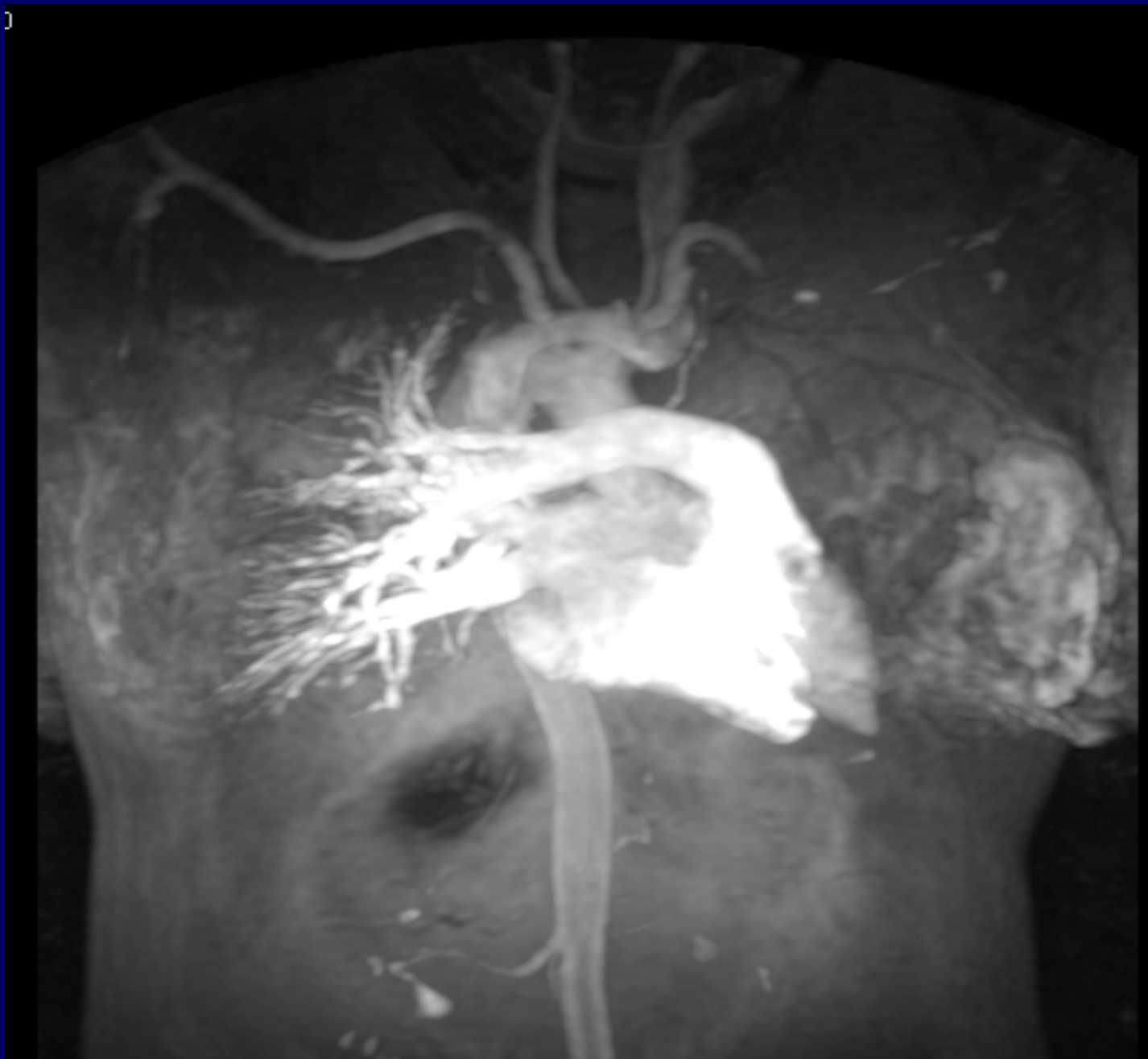












- Anomalous right-sided aortic arch.
- Aplastic left pulmonary artery.