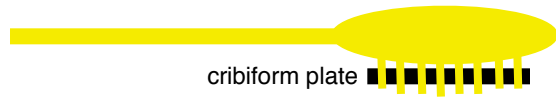
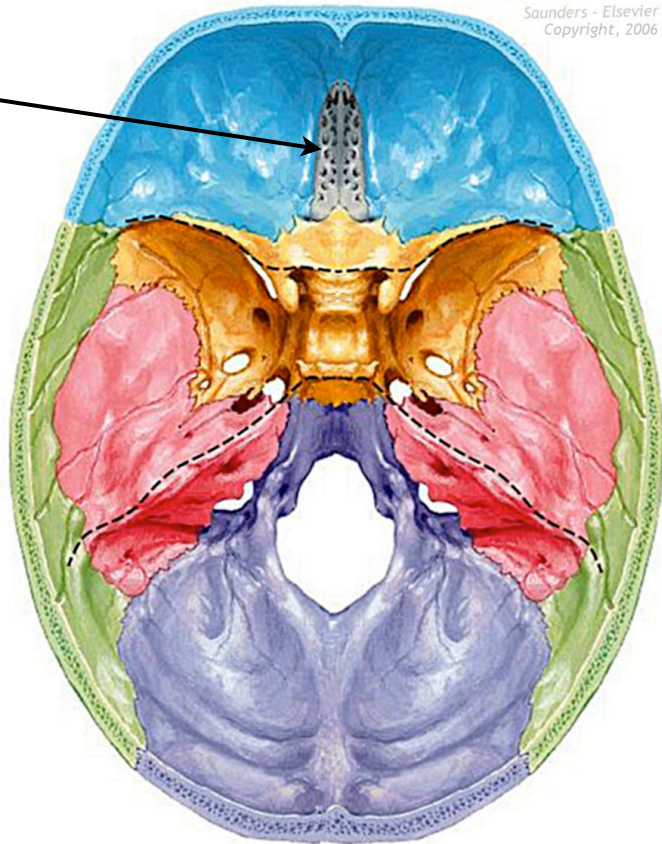



Cranial Nerve I

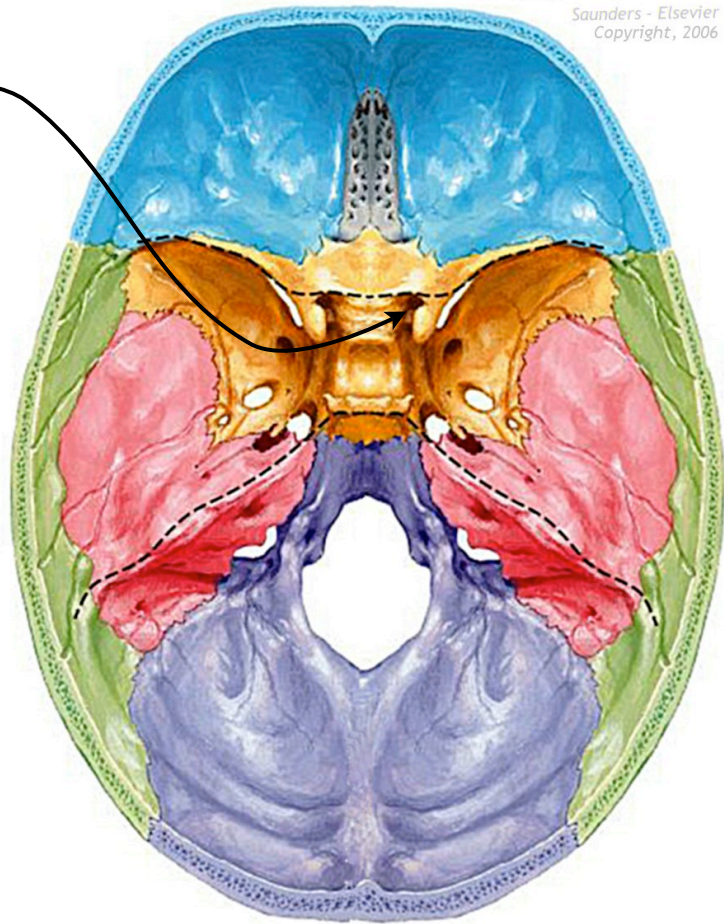
- Name:** Olfactory nerve
- Foramen:** Cribriform plate
- Fiber Type:** Special sensory
- Function:** Olfactory bulbs, Smell
- Branches:** Olfactory filaments
- Embryo:** CNS (ectoderm)



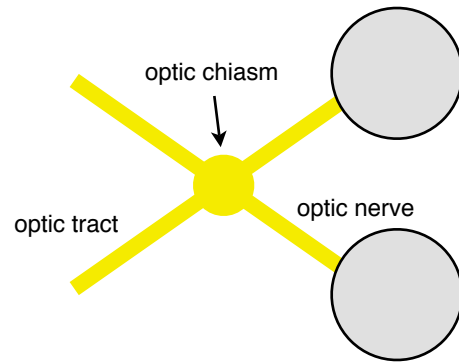
sensory = 


Cranial Nerve II

- Name:** Optic nerve
- Foramen:** Optic canal
- Fiber Type:** Special sensory
- Function:** Retina, vision
- Branches:** None
- Embryo:** Diencephalon
- Other:** Optic chiasm is in front of pituitary



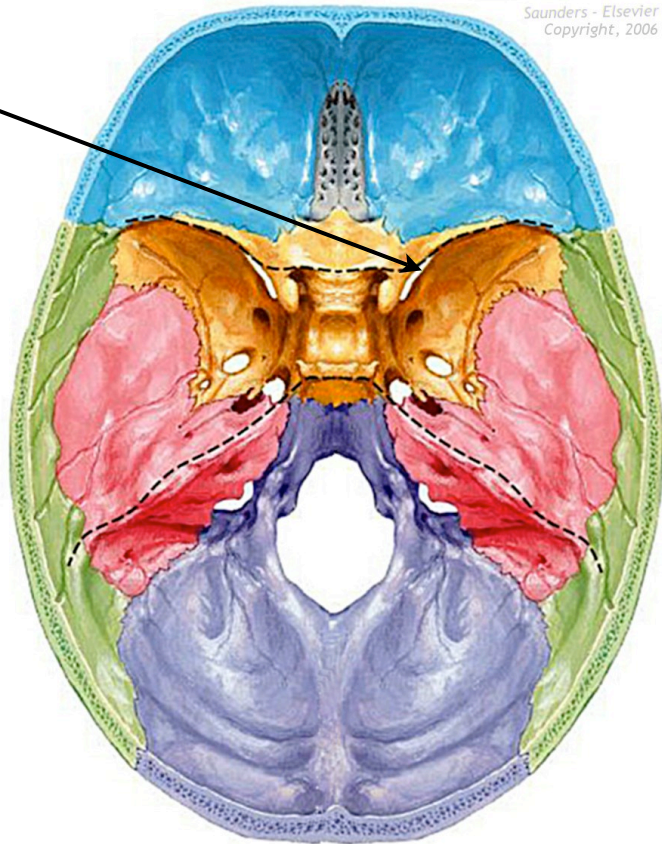
Saunders - Elsevier
Copyright, 2006



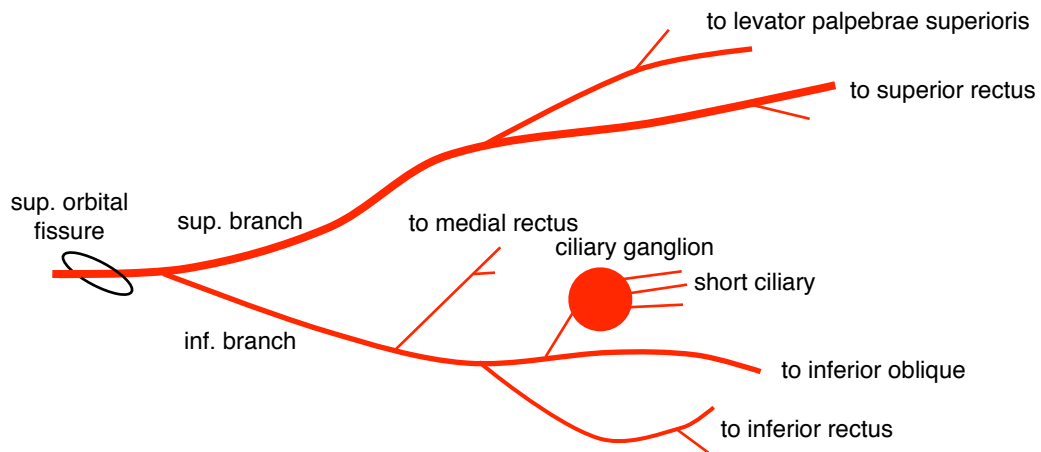
sensory = 

Cranial Nerve III

- Name:** Oculomotor
- Foramen:** Superior orbital fissure
- Fiber Type:** General somatic motor, Parasympathetic
- Function:** *General somatic motor:*
1. superior rectus
 2. levator palpebrae superioris
 3. medial rectus
 4. inferior rectus
 5. inferior oblique
- Parasympathetic*
1. sphincter pupillae
 2. ciliary muscle
- Branches:** 1. superior branch
2. inferior branch
- Embryo:** Mesencephalon



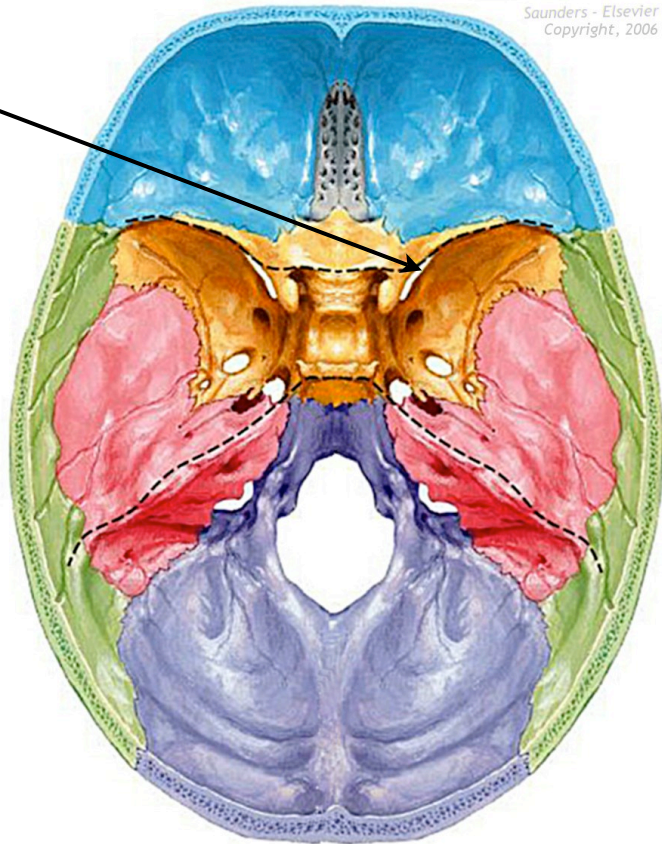
Saunders - Elsevier
Copyright, 2006



motor = —

Cranial Nerve IV


- Name:** Trochlear
- Foramen:** Superior orbital fissure
- Fiber Type:** General somatic motor
- Function:** *General somatic motor:*
1. superior oblique
- Branches:** muscular
- Embryo:** Mesencephalon



Saunders - Elsevier
Copyright, 2006

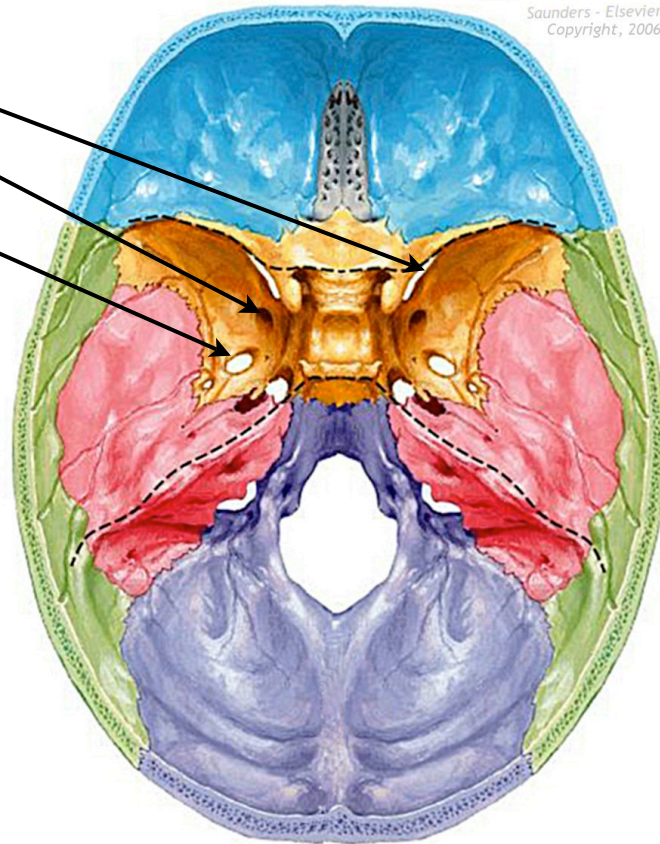
sup. orbital
fissure



motor = 

Cranial Nerve V

- Name:** Trigeminal
- Foramen:** V1: sup. orbital fissure
V2: foramen rotundum
V3: foramen ovale
- Fiber Type:** General somatic motor,
General somatic sensory
- Embryo:** Metencephalon
- Branches:** V1 - *ophthalmic*
1. meningeal
 2. frontal
 3. lacrimal
 4. nasociliary
- V2 - *maxillary*
1. meningeal
 2. infraorbital
 3. post/ant superior alveolar
 4. zygomatic
 5. sensory roots to pterygopalatine ganglion
 6. greater/lesser palatine
- V3 - *mandibular*
1. meningeal
 2. auriculotemporal
 3. buccal
 4. lingual
 5. inferior alveolar
- Function:** V1 - *ophthalmic (sensory)*
1. meninges
 2. orbit (cornea conjunctiva)
 3. nasal cavity lining
 4. forehead
 5. middle nose
 6. frontal air sinuses

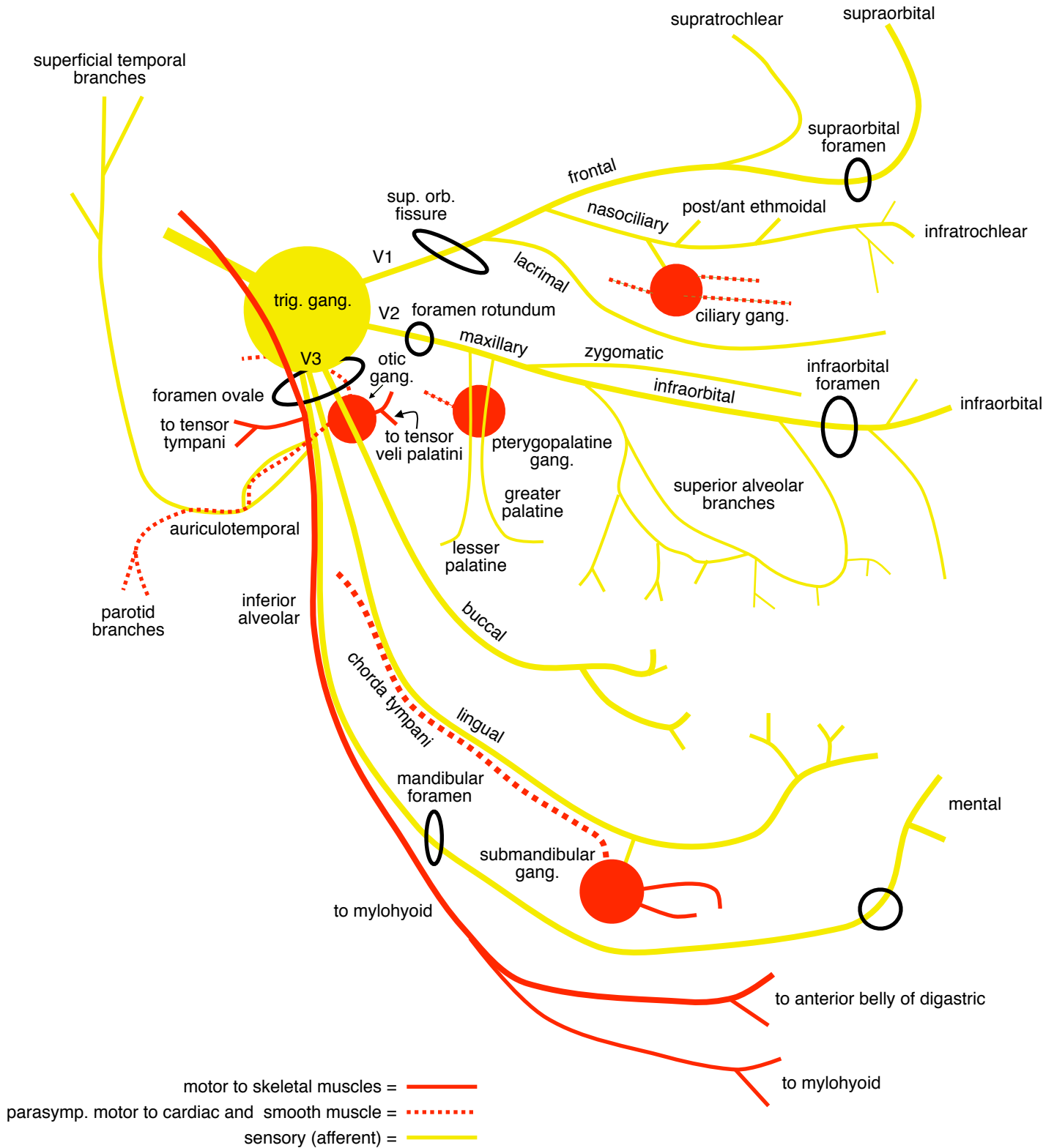


- Function:** V2 - *maxillary (sensory)*
1. meninges
 2. maxillary air sinus
 3. gums/teeth of upper jaw
 4. bony part of cheek

- V3 - *mandibular (sensory)*
1. meninges
 2. mucosa of oral cavity/palate
 3. ant. 2/3 of tongue (general)
 4. gums/teeth of lower jaw
 5. soft part of cheek/mandible


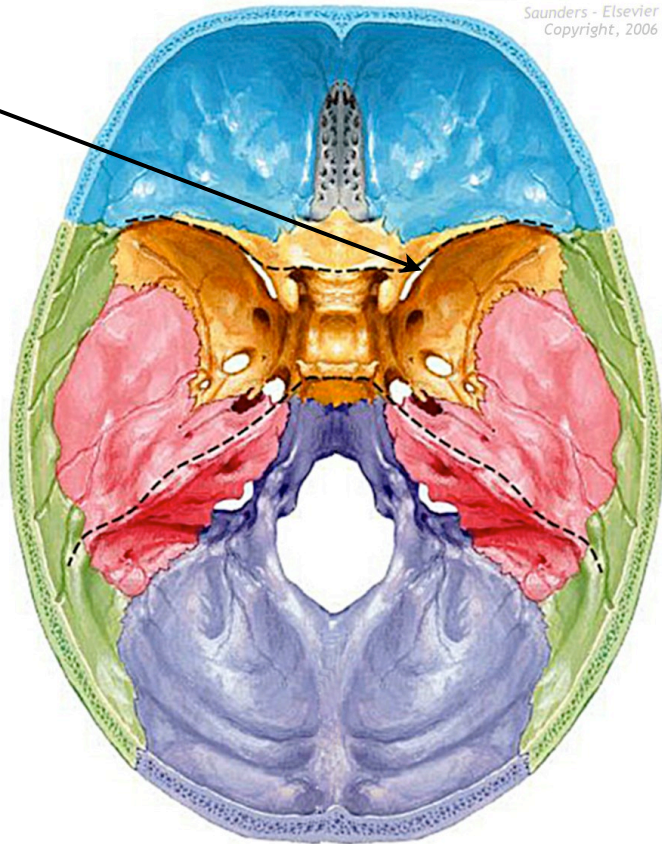
- V3 - *mandibular (motor)*
1. masseter
 2. buccinator
 3. lateral pterygoid
 4. medial pterygoid
 5. tensor tympani
 6. tensor palatini
 7. mylohyoid
 8. ant. belly of digastric
- } muscles of mastication


Cranial Nerve V (cont...)



Cranial Nerve VI

- Name:** Abducens
- Foramen:** Superior orbital fissure
- Fiber Type:** General somatic motor
- Function:** *General somatic motor:*
1. lateral rectus
- Branches:** None
- Embryo:** Metencephalon



motor = 

Cranial Nerve VII

Name: Facial

Foramen: Internal acoustic meatus

Fiber Type: Special sensory
General sensory
Branchiomotor
Parasympathetic motor

Function: *Branchiomotor:*

1. muscles of facial expression
2. post. belly of digastric
3. stylohyoid

Special sensory:

1. taste ant. 2/3 of the tongue

General sensory:

1. skin of auricle
2. skin of small area behind ear

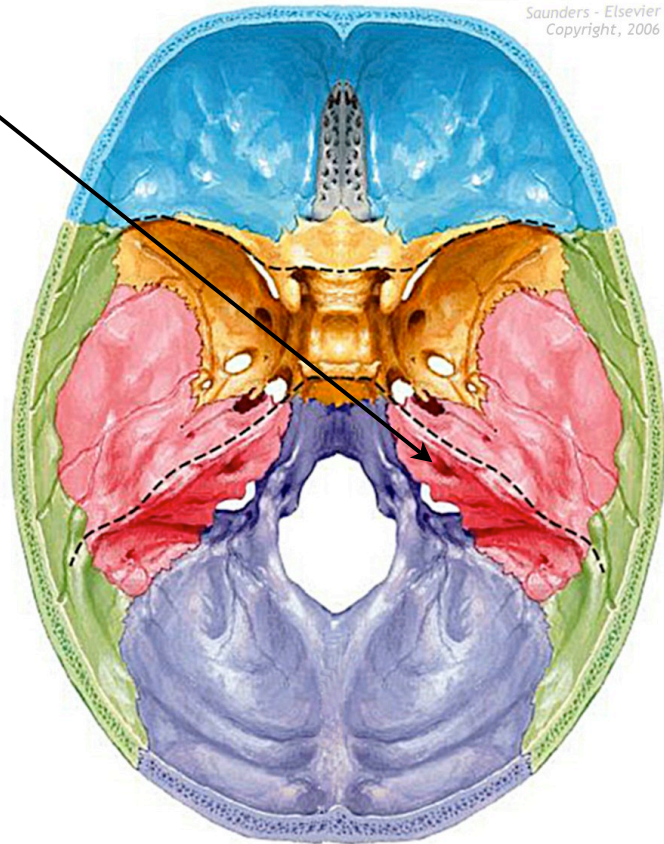
Parasympathetic:

1. lacrimal gland
2. submandibular gland
3. sublingual gland
4. mucous membranes of nasopharynx, hard and soft palate

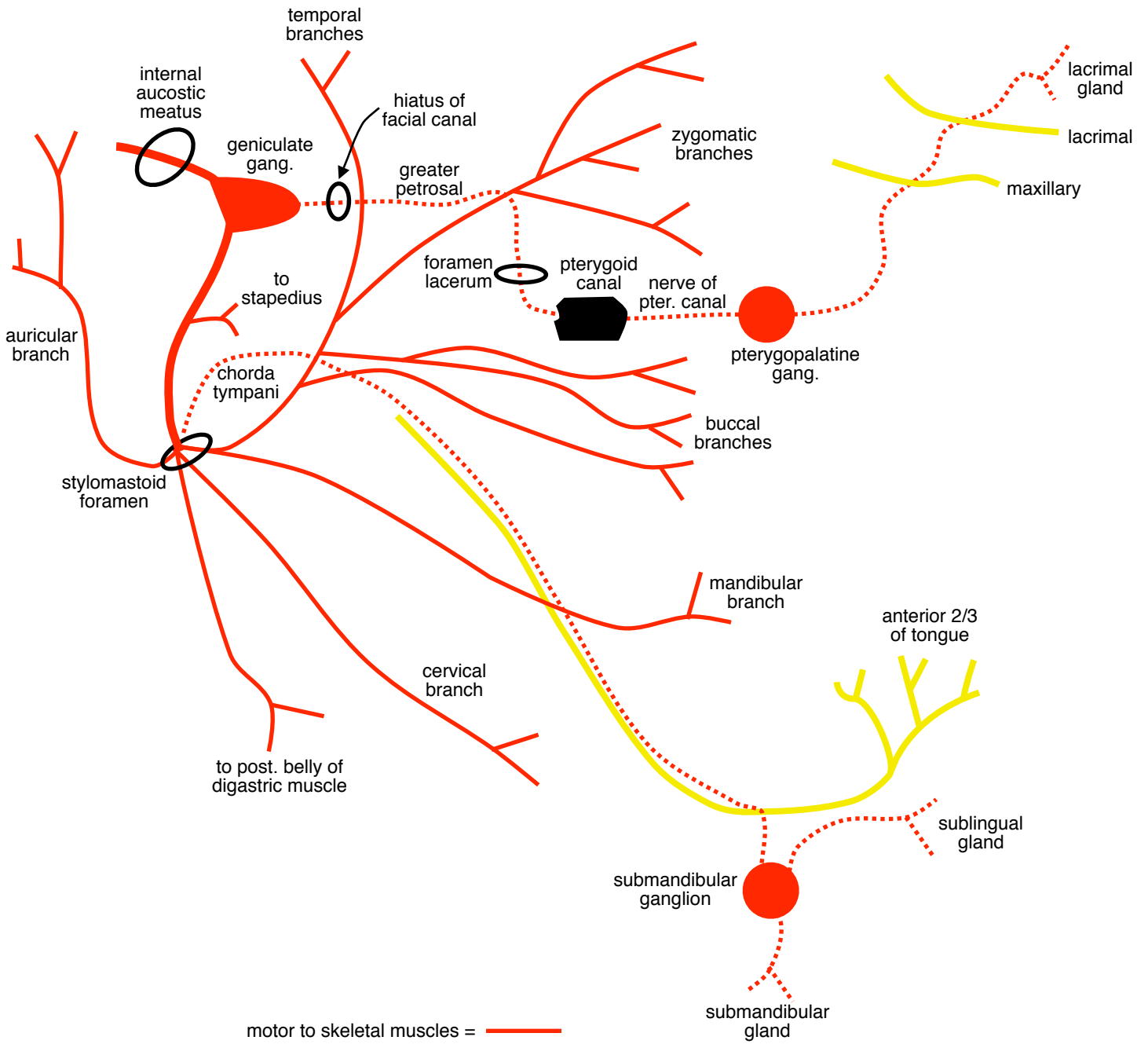
Branches: *Branchiomotor:*

1. temporal
2. zygomatic
3. buccal
4. mandibular
5. cervical
6. post. auricular
7. branch to post. belly of digastric
8. stylohyoid

Embryo: Metencephalon




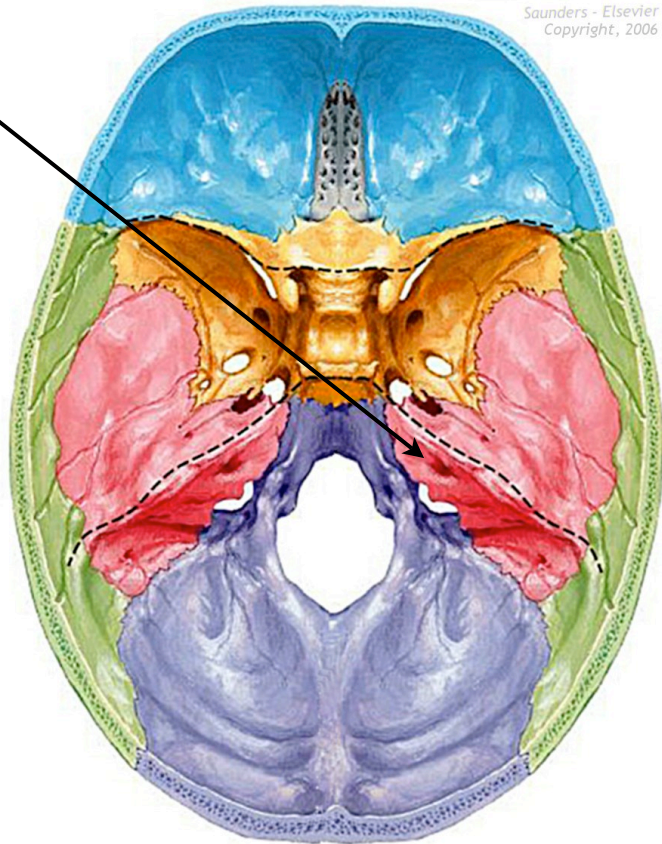
Cranial Nerve VII (cont...)



motor to skeletal muscles = ————
 parasymp. motor to cardiac and smooth muscle =
 sensory (afferent) = ————

Cranial Nerve VIII

- Name:** Vestibulocochlear
- Foramen:** Internal acoustic meatus
- Fiber Type:** Special sensory
- Function:** *Special sensory*
 - 1. hearing
 - 2. balance
- Branches:** None
- Embryo:** Metencephalon



sensory (afferent) = 

Cranial Nerve IX

Name: Glossopharyngeal

Foramen: Jugular foramen

Fiber Type: Special sensory
General sensory
Branchiomotor
Parasympathetic

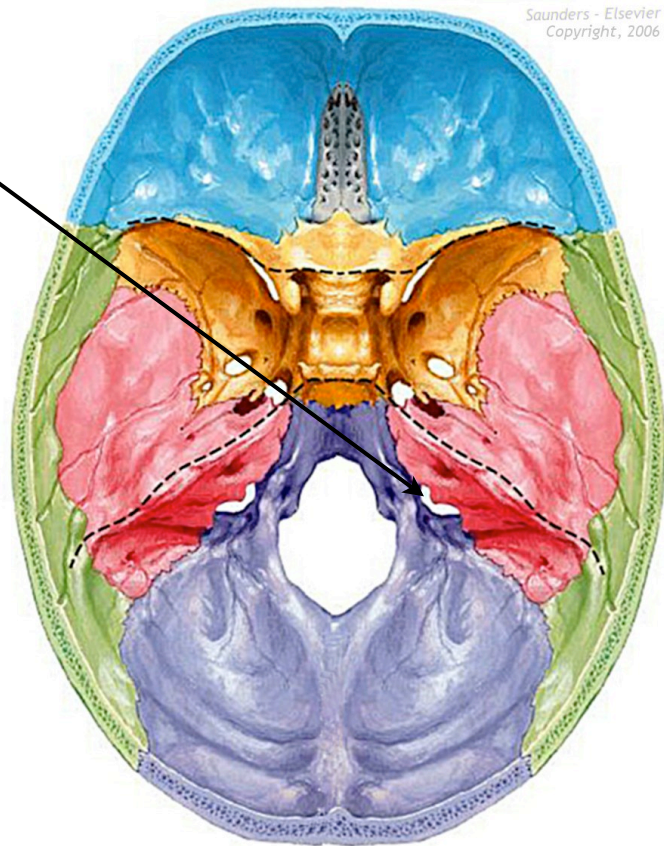
Function: *Special/general sensory*
1. taste to post. 1/3 of tongue
2. pharynx
3. carotid sinus
4. carotid body

Branchiomotor
1. stylopharyngeus

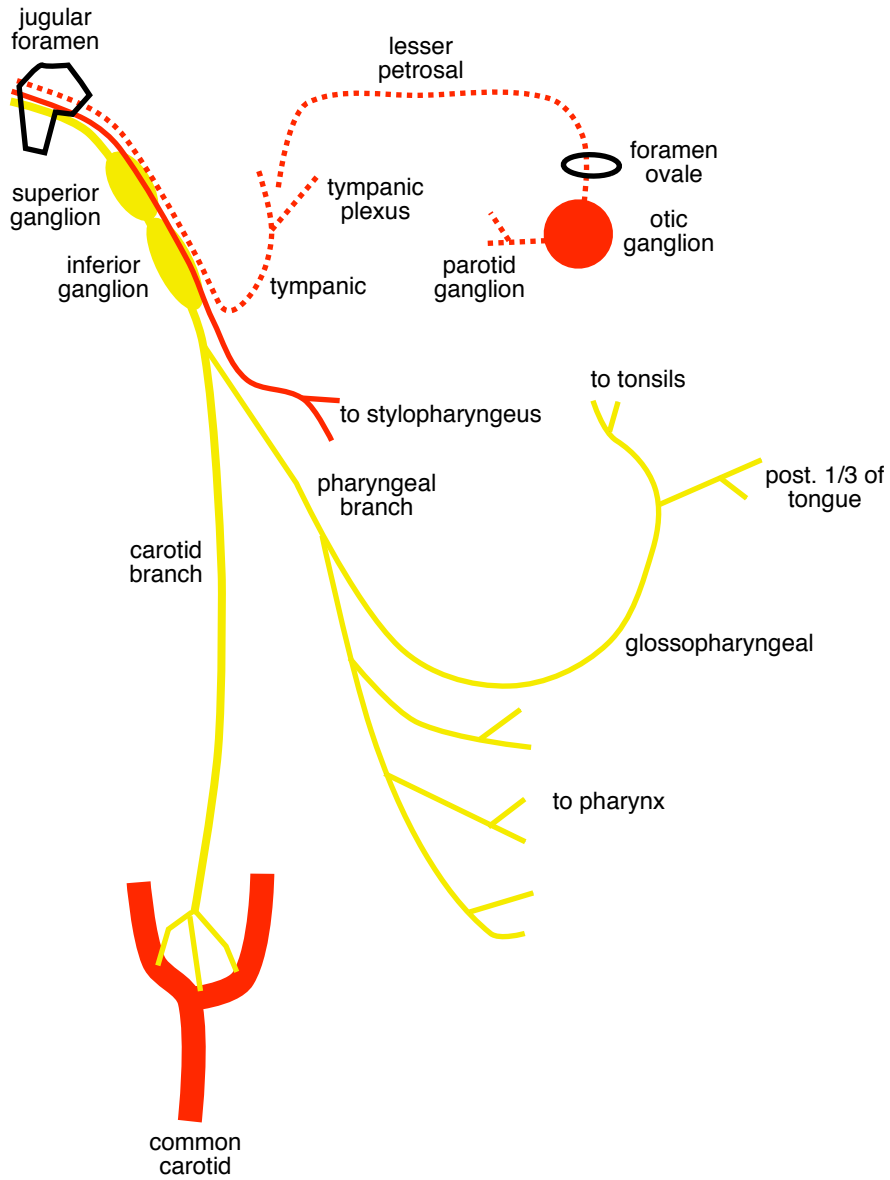
Parasympathetic
1. parotid gland

Branches: None

Embryo: Myelencephalon



Cranial Nerve IX (cont...)



motor to skeletal muscles = ————
parasymp. motor to cardiac and smooth muscle =
sensory (afferent) = ————

Cranial Nerve X

Name: Vagus

Foramen: Jugular foramen

Fiber Type: *General sensory*
Visceral sensory
Special sensory
Branchiomotor
Parasympathetic

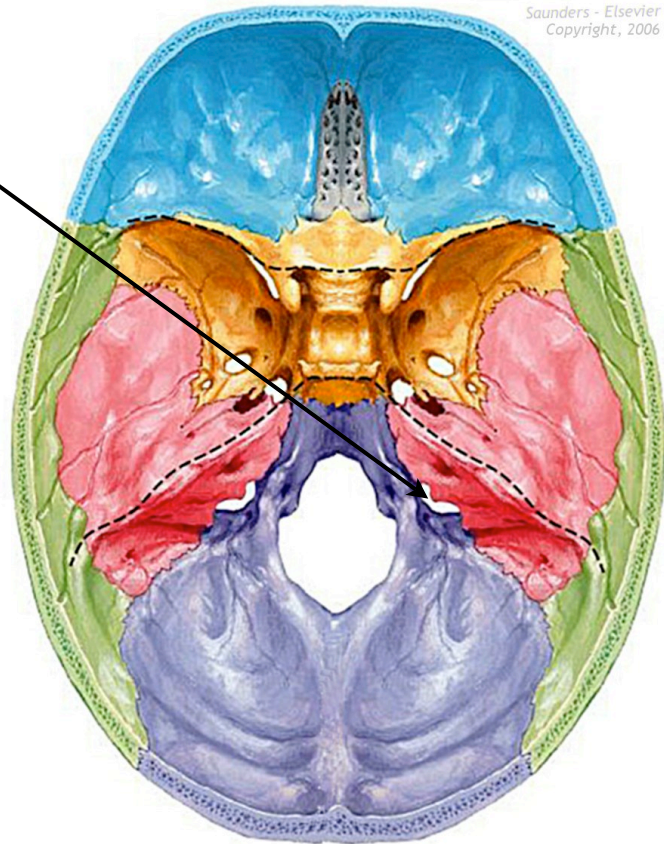
Function: *Sensory*
1. larynx mucosa
2. epiglottic taste

Motor
1. pharynx
2. larynx
3. soft palate
4. upper 2/3 of esophagus (for speech/swallowing)

Parasympathetic
1. Preganglionic fiber to thoracic and abdominal smooth muscle, viscera, glands

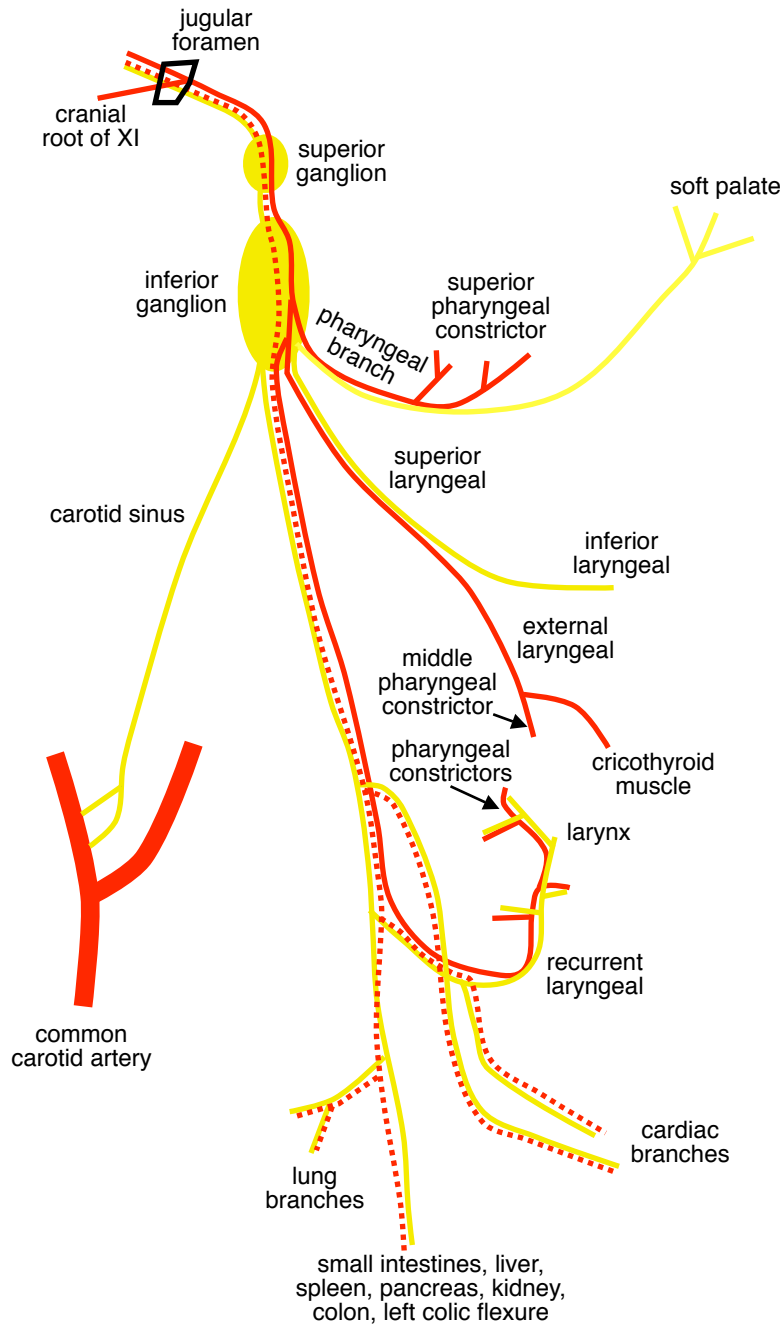
Branches: None

Embryo: Myelencephalon



motor = —

Cranial Nerve X (cont...)

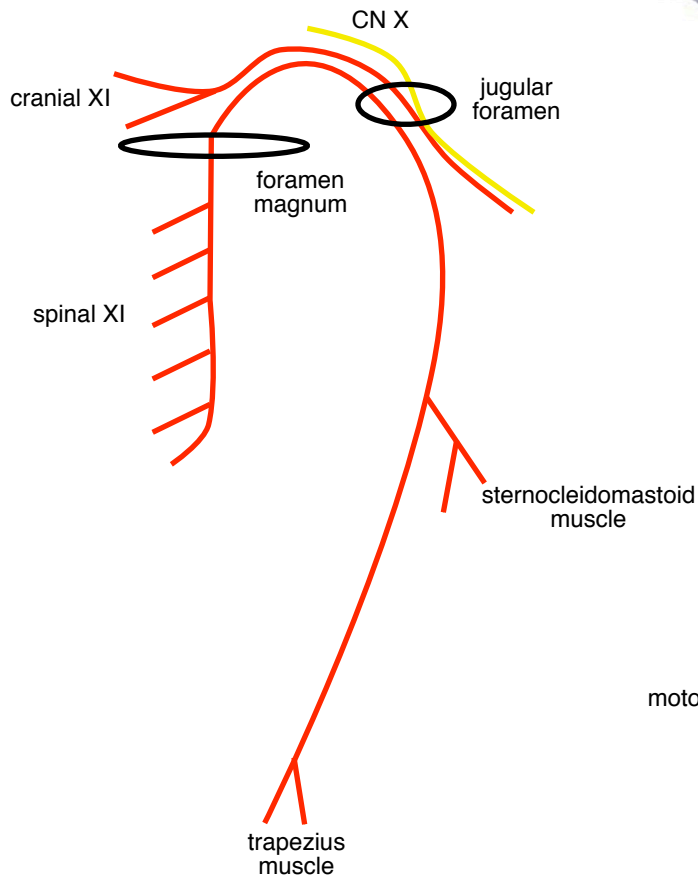
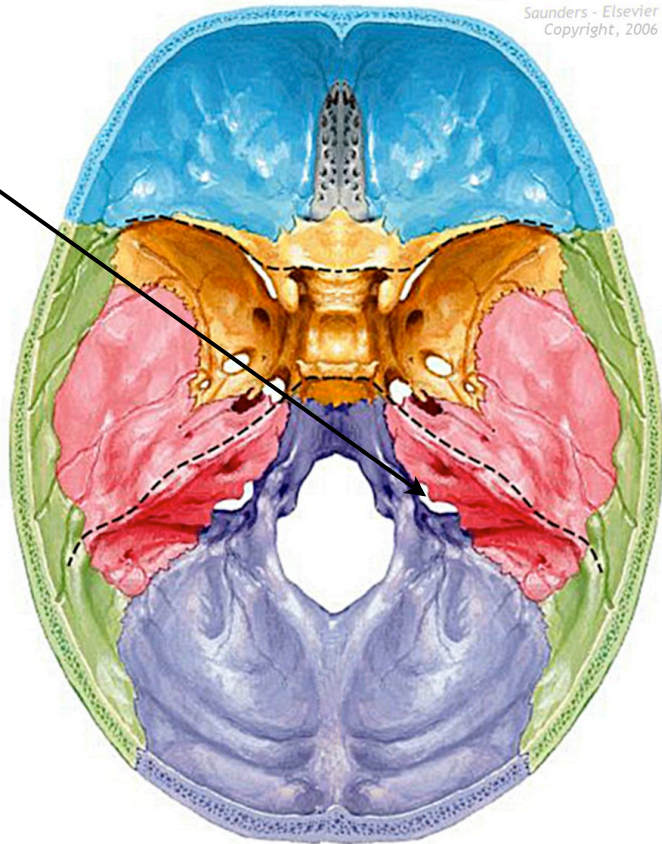


motor to skeletal muscles = —
 parasymp. motor to cardiac and smooth muscle = ⋯
 sensory (afferent) = —

Cranial Nerve XI

- Name:** Spinal accessory
- Foramen:** Jugular foramen
- Fiber Type:** Motor
- Function:** *Motor*
 - 1. sternocleidomastoid
 - 2. trapezius
- Branches:** Muscular
- Embryo:** Cervical spine

Saunders - Elsevier
Copyright, 2006



Cranial Nerve XII

- Name:** Hypoglossal
- Foramen:** Hypoglossal canal
- Fiber Type:** General somatic motor
- Function:** *General somatic motor:*
 - 1. All tongue muscles except palatoglossus
- Branches:** None
- Embryo:** Myelencephalon

