

How to Remember Anatomy Concepts

Brachial Plexus

Randy Travis **D**rinks **C**old **B**eers
Rami Trunk **D**ivision **C**ord **B**ranch

Basilic Vein vs Cephalic Vein

Basilic vein is closer to **B**ody

Thoracoacromial Artery

ACPD – Atlantic City Police Department
TA supplies **a**cmion, **c**lavicle, **p**ectoral, **d**eltoid muscles

Lumbrical Action

Lumbrical action is to hold a pea with the hand in an “L” shape
Metacarpophalangeal joint flexed while interphalangeal joint extended

Intertubercular Groove

“The **l**ady between **t**wo **m**ajors”
Teres **m**ajor is in medial lip of groove
Pectoralis **m**ajor is on lateral lip
Latissimus (Lady) is on floor of groove between majors

Rotator Cuff

The **SITS** muscles
First 3 are in greater tubercle
Only the last one is in lesser tubercle
Supraspinatus in supraspinous fossa
Infraspinatus in infraspinous fossa
Teres minor on lateral border
Subscapularis in subscapular fossa

Flexor Digitorum

Superficialis splits in two,
To permit **P**rofundus passing through

Brachioradialis

Brachio**R**adialis
Beer **R**aising muscle – flexes elbow best when wrist in beer holding orientation
Breaks **R**ules for innervation – flexor muscle, **B**ut **R**adial
Behind it is **R**adial nerve in cubital fossa
Attaches **B**ottom of **R**adius

Extensor Expansion

The **eX**tensor **eX**pansion is on the **proX**imal **phalynX**

Flexing Elbow

Three **B**'s **B**end the **e**l**B**ow
Brachialis
Biceps
Brachioradialis

Anterior Forearm muscles - Superficial

Place thumb in palm and lay hand palm down on arm like picture

The 4 fingers show distribution PFPF (pass/fail/pass/fail)

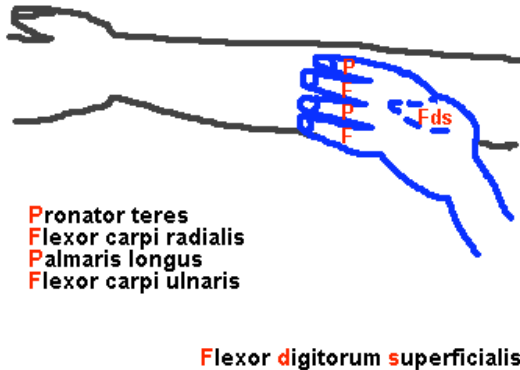
Pronator teres

Flexor carpi radialis

Palmaris longus

Flexor carpi ulnaris

Deep to the others: **Flexor digitorum superficialis**



Interossei Muscles of Dorsal/Palmar in Hand

“PAd” and “DAB”

The Palmar ADduct and the Dorsal ABduct

Use **hand** to **dab** with a **pad**

Serratus Anterior Innervation

SALT

Serratus Anterior = Long Thoracic

Intrinsic Muscles of Hand (palmar surface)

“A OF A OF A”

Thenar, lateral to medial:

Abductor pollicis longus

Opponens pollicis

Flexor pollicis brevis

Adductor pollicis

Hypothenar, lateral to medial:

Opponens digiti minimi

Flexor digiti minimi

Abductor digiti minimi

Erector Spinae Muscles

I Love Sports

Lateral to medial

Iliocostals

Longissimus

Spinalis

Biceps Brachii Muscle Origins

"Its a **short** distance to the **corner**. Its a **long** distance to the **supra**highway."

Short head origin on **cor**acoid process

Long head origin on **supra**glenoid cavity

Deltoid proximal attachments

Deltoid **CLASPs**

Clavicle

Acmion

Spine of scapula`