
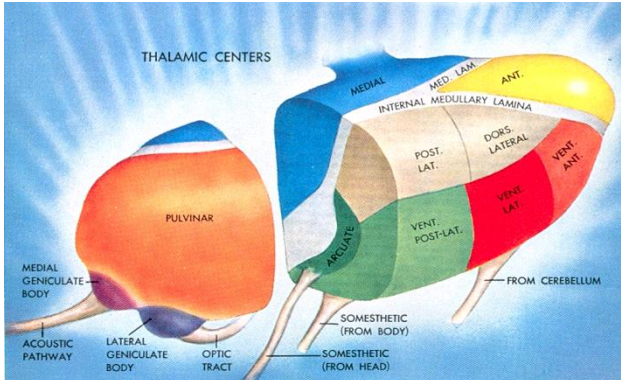


# THALAMUS

## ANATOMY

<p><b>DIENCEPHALON</b></p>  <p>Thalamus, epithalamus (pineal body, habenula, posterior commissure), hypothalamus, subthalamus (lat to hypothal)</p>	<p><b>THALAMUS</b></p>  <p>LGN, MGN, Pulvinar, LP, VPL/VPM, LD, VA/VL, AN, MD, IML</p>
--	--

## CONNECTIONS

Input	Thalamic nucleus	Output
Optic tract	LGN	Primary visual cortex
Inferior colliculus (via brachium)	MGN	Areas 41,42 (auditory)
ML, trigem, taste, neospinothal	VPL/VPM	Primary somatosensory cortex
Cerebellum, GlobPall, SubsNigra	VA/VL	Premotor cortex
Hippocampus (via fornix), MMB	AN	Cingulate cortex
Amygdala, hypothalamus	MD	Prefrontal cortex
Hippocampus (via fornix)	Lat Dorsal	Cingulate cortex
Sup. colliculus, primary visual cx	Pulvinar (and Lat posterior)	Association cortices
*Internal Medullary lamina (IML) → diffuse projections		
*Thalamic reticular nucleus (thin sheet of cells on lateral aspect of thal) → inhibitory to other thal nuclei		

## FUNCTIONS OF THE THALAMUS

- 1) Relay all sensory information to cortex (except olfactory – direct to cortex)
- 2) Selective gating of signals
- 3) Drivers (strong, only need 10% to activate) vs Modulators (weak –need many to mod. response)

## INTERNAL CAPSULE

- A. Function: carries thalamic fibers to cortex, carries fibers from frontal cx to brainstem
- B. Anatomy: anterior limb separates caudate nucleus from putamen/GP; posterior limb separates thalamus from putamen/GP; most medial part = genu (caudate-thalamic junction)
- C. Connections

Anterior limb	Anterior nucleus to cingulate cx MD to prefrontal cx	Frontal lobe fibers to pontine nuclei
Genu	VA/VL to motor/premot cortices	Frontal –pontine
Posterior limb	VA/VL to motor/premotor cx VPL/VPM to postcentral gyrus	Corticospinal/corticobulbar fibers
Retrolenticular limb	Pulvinar, LP to association cxs LGN to calcarine sulcus	Parietal lobe to pontine nuclei
Sublenticular limb	LGN to calcarine sulcus MGN to superior temporal gyrus	